Research Article

BIOMEDICAL Journal of Scientific & Technical Research

ISSN: 2574 -1241

DOI: 10.26717/BJSTR.2026.67.010483

Double Chambered Right Ventricle-a Possible Companion of VSD with High Trans Ventricular Gradient is the Term "VSD Fallotisation" Obsolete?

Ivan Malčić[1]*, Lidija Srkoč Majčica[2], Stanko Težak[3] and Dražen Belina[4]

[1]*Department of Pediatric Cardiology, Clinic of Pediatrics, University Hospital Center Zagreb, Croatia*

[2]*Department of Pediatric Cardiology, Clinic of Pediatrics Srebrnjak, Croatia*

[3]*Department of Nuclear Medicine, University Hospital Center Zagreb, Croatia*

[4]*Department of Pediatric Cardiac Surgery, Clinic of Cardiac Surgery; University Hospital Center Zagreb, Croatia*

***Corresponding author:** Prof. Dr. Sci. Ivan Malčić, Department of Pediatrics, University Hospital Center Zagreb. Department of Pediatric Cardiology, Kišpatićeva 12, 10 000 Zagreb, Croatia

ARTICLE INFO

Received: October 02, 2026

Published: November 17, 2026

Citation: Ivan Malčić, Lidija Srkoč Majčica, Stanko Težak and Dražen Belina. Double Chambered Right Ventricle-a Possible Companion of VSD with High Trans Ventricular Gradient is the Term "VSD Fallotisation" Obsolete?. Biomed J Sci & Tech Res 67(3)-2026. BJSTR. MS.ID.010483.

ABSTRACT

Aim: The aim of this paper is to present the clinical characteristics and results of surgical treatment of five patients with double chambered right ventricle (DChRV) as a possible consequence of ventricular septal defect (VSD). In this paper, we would like to express the opinion that the diagnosis of "VSD Fallotisation", which is still used in practice, is incorrect from a morphological, hemodynamic and functional point of view.

Research Results: In five children (4F) aged 2.3 to 11.3 (mean age 6.3) years, an intracavitary gradient of the right ventricle due to aberrant muscle bundles was diagnosed. All patients had VSD with hemodynamically insignificant left-to-right shunt (Qp/Qs from 10 to 31%). In three children, DChRV developed with primary VSD, in one with a residual defect after closure of the peri membranous VSD with a patch, and in one, DchRV was detected approximately 4 years after a properly primary VSD closure with a patch. The intracavitary right ventricular gradient was measured with an end-hole catheter in the range of 50 to 90 mmHg. Two patients had no subjective cardiac complaints, and in three patients' fatigue was described during increased exertion. In one patient with DchRV the VSD was located proximal to the septal defect (peri membranous), and in two patients it was distal (subaortic-supracrystall or conal-double committed). One patient had two VSDs, one located proximal and the other distal to the RV stenosis. So far, the defect has been corrected by cardiac surgery in three patients with patch plastic of the VSD and removal of the obstruction in the right ventricle by resection of the aberrant musculature, all at the age of 2 years and 7 months to 6 years and 3 months. The same procedure is planned in another patient, while in the other one isolated resection of the aberrant bundle is planned. There were no postoperative complications or subjective symptoms of a cardiac nature in our patients, and the maximum intracavitary gradient postoperatively was 20 mmHg.

Conclusion: Right ventricular remodeling is probably caused by the existence of a peri membranous or supracrystall VSD, and it can develop in primary or residual (postoperative) VSD, but also in properly surgically closed VSD. Therefore, patients with VSD, especially peri membranous and supracrystall, need to be monitored for a long time at longer intervals and after surgery. This is of particular importance because of the possibility of recurrence of the septation, the possible appearance of a subaortic membrane and/or aortic valve insufficiency. Surgical removal of hypertrophic and aberrant tissue is an adequate form of treatment with relatively rare serious complications, which, given the expected progressive course of the disease, justifies surgery in cases of significant obstruction of the DChRV, even in the absence of symptoms.

Keywords: Double Chambered Right Ventricle; Ventricular Septal Defect; Children; Negation of the Term "Fallotisation of the VSD".

Interpretation of Abbreviations: DChRV: Double Chambered Right Ventricle; VSD: Ventricular Septal Defect; Qp/Qs: Ratio of Pulmonary (P) To Systemic (S) Circulation (Q = Quantity = Minute Volume); DORV: Double Outlet Right Ventricle; ToF: Tetralogy of Fallot; DV: Right Ventricle; LV: Left Ventricle; L-D: Left-Right; PVR: Pulmonary Vascular Resistance

Introduction

Double chambered right ventricle (DChRV) is a rare disorder in which an anomalous muscular bundle of hypertrophic trabeculae or aberrantly positioned sept marginal trabeculae divides the right ventricle into a proximal, high-pressure, thickened, hypertrophic-walled portion and a distal, low-pressure, thin, smooth-walled portion [1]. In cases where anomalous musculature or atypical sept marginal trabeculae are present, DChRV may be considered a congenital heart defect, but in most patients described cases, it arises postnatally from progressive hypertrophy of the supraventricular ridge or other muscular structures within the right ventricle [2,3]. It is, in fact, a sub-infundibular obstructive lesion of the right ventricle [4]. Since this obstruction is discovered late, most often after surgery for peri membranous VSD or with the diagnosis of supracrustal VSD with low L-R shunt, it is possible that it manifests itself only in adulthood with subjective symptoms of right ventricular heart failure due to its hypertrophy, with a loud murmur. Due to the high intraventricular gradient on the right, this phenomenon is still referred to in practice as "Fallotisation of the VSD". Given the possibly erroneous view about the subsequent and late appearance of Tetralogy of Fallot, we believe that this is a condition that does not correspond to TF morphologically, functionally, or hemodynamically, and certainly cannot be classified in Clark's etiopathogenetic classification (Cono truncal malformations). Therefore, we believe that this is an erroneous term that should be excluded from cardiological terminology.

Right ventricular septal defect is found in approximately 0.5–2% of individuals with congenital heart defects [2] and has been observed in 1:3600 autopsies [5]. As many as 11% of patients described by Kahr, et al. [6] had trisomy 21. In 80–90% of cases, DchRV is associated with other associated heart defects, primarily peri membranous VSD. Associated errors can be VSD of other locations, subaortic stenosis, pulmonary valve stenosis, double outlet right ventricle (DORV), tetralogy of Fallot (ToF), anomalous pulmonary vein return, corrected transposition of the great arteries, pulmonary atresia with an intact ventricular septum, Ebstein's anomaly, subaortic crest, aortic insufficiency, tricuspid insufficiency, infundibulum aneurysms, open foramen ovale and mitral valve prolapse [6-8]. The frequent association of DChRV and VSD and the progressive course of the disease indicate reactive hypertrophy of the muscle tissue of the right ventricle in response to a strong turbulent flow from left to right [9]. It can be manifested already in the newborn age, and most often the diagnosis is made in early childhood [10,11]. The disease is typically progressive [11], and many patients are asymptomatic despite a high right ventricular pressure gradient. The disorder may eventually result in decreased exercise tolerance, loss of consciousness, precordial pain, and even heart failure [12]. The delayed onset of symptoms and their nonspecific nature are partly responsible for the late diagnosis. A possible reason for the late diagnosis is the description of the primary cardiological examination in which no septation is yet found (or it is not paid attention to), where only the finding of a VSD committal after closure of the peri membranous VSD (residual L-D flow) dominates, or the primary finding is a supracrystall (double committed) small VSD without hemodynamic burden, but with a high LV-DV gradient. We do not find in the literature that DchRV is associated with a previous subaortic (membranous) VSD, which makes sense if we follow our assumption. Namely, membranous VSD is most often part of TF, and if isolated, it progresses to pulmonary hypertension.

It seems that a high trans ventricular gradient that lasts longer is the reason for reactive hypertrophy of the right ventricular musculature due to a strong jet, which is found precisely in peri membranous and supracrustal VSD. Due to the progressive nature of the disease, some authors suggest early resection of obstructive bundles even in asymptomatic patients [13-16]. However, the indications for surgical treatment of asymptomatic patients are still not clearly defined [17]. The purpose of our paper is to familiarize the reader with the diagnostic and therapeutic approach to this rare entity, with the aim of presenting the clinical characteristics and results of surgical treatment of five patients with DChRV as a possible consequence of a small VSD, either primary or postoperative (residual).

Patients and Diagnostic Methods

We present 5 patients diagnosed and treated at the Department of Pediatric Cardiology, University Hospital Centre Zagreb, who were diagnosed with DChRV between May 2015 and October 2017. These were five children (4F and 1M) aged between 4 and 11 years (mean age 7.65 years). All had been followed up cardiological since infancy (0-4 months; mean age 1 month). The reason for referral to pediatric cardiology was a precordial murmur with features suggesting the presence of VSD, which was confirmed in all cases by a complete cardiological workup, including cardiac ultrasound, radioangioscintigraphy and angiocardiography. Right ventricular remodeling was observed between the ages of 2 years and 4 months and 11 years and 3 months (mean age 6.33). On auscultation, a systolic ejection murmur of the highest intensity was heard along the left sternal border in the middle, with upward propagation. The intensity of the second heart sound was variable. All the features of the findings in children with double right ventricles are described in Table 1 (Table 1).

Table 1: Clinical characteristics of patients with double chambered right ventricle.

Patient	Gender	Reason for referral	VSD	Associated defects	Age at dg. VSD	Qp/Qs (%-RAS) PVR WU	Previous surgical procedures	Age at DChRV dg	Clinical Symptoms	Gradient in RV (cath.)	Relation VSD-obstruction
1 (BE)	F	Murmur	Peri membranous + sub aortal (two VSDs)	ASD II	After birth	<10% 1 WU		2 yr 4 mo	None	>80 mmHg	Proximally and distally (two VSDs)
2 (MK)	M	Murmur	Peri membranous	Mild PS –PV dys-plasia +MPA hypopl.	After birth	28% (1,39) 1,2 WU	VSD patch closure	6 yr 2 mo	Exercise intolerance	70 mmHg	Proxymal
3 (SZ)	F	Murmur	Subaortic supracrustal	AI, subaortic membrane	After birth	10% (1,1 WU) 1,6		4 yr 2mo	None	80 mmHg	Dystal
4 (SA)	F	Murmur	Perimembranous	None	1 mo.	31% (1,44) 2,7WU		7yr 9 mo	Exercise intolerance	60 mmHg	Proxymal
5 (II)	F	Murmur	Subaortic	Infundibular and Valvular PS	4 mo	16% (1,18) 1,8WU	VSD patch closure + trans-annular patch (PV)	11 yr 3mo	Exercise intolerance	50 mmHg	Dystal

Abbreviations: AI–aortic insufficiency; ASD–atrial septal defect; RSA–right subclavian artery; DChRV–double chambered right ventricle; dg–diagnosis; RV–right ventricle; yr - year; hypopl. – hypoplasia; cath. – catheter; m - male; mth - month; PS–pulmonary stenosis; PV–pulmonary valve; MPA-main pulmonary artery; VSD–ventricular septal defect; F-female; cath-catheterisation; RAS – radioangioscintigrafija.

The diagnosis of DChRV was made based on transthoracic ultrasound examination and cardiac catheterization. Considering the age of the children, the echocardiographic window was satisfactory and adequate visualization of all structures was possible with transthoracic ultrasound. Consciences to determine the location of the flow acceleration, both continuous and colour-Doppler were performed, and the pressure gradient was quantified using the simplified Bernoulli equation (Figure 1A, 1B & 1C). Both left and right catheterization were performed in all patients. The pressure gradient was determined using an end-hole catheter and withdrawn from the pulmonary artery, through the right ventricular outflow tract to the right atrium. Using a retrograde arterial approach, pressure gradients were measured on the left side in a similar manner. The right ventricle was angiocardiographic ally visualized from the posteroanterior and lateral projections, and all patients also had left ventriculography (Figures 2A, 2B & 2C). In addition to oximetry, the flow rate was also assessed by radioangioscintigraphy due to the higher sensitivity of radioangioscintigraphy compared to Fick oximetry analysis (Table 1). All flows were hemodynamically insignificant, with low PVR values (Table 1).

 DOI: 10.26717/BJSTR.2026.67.010483

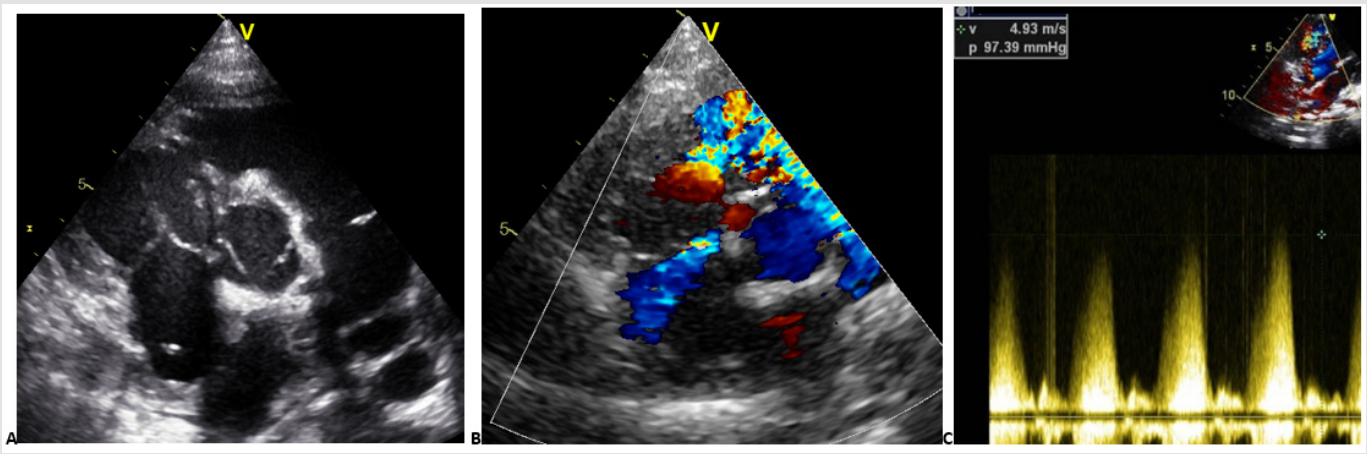

Abbreviations: AO–aorta; DA – right atrium; DV; RV– right ventricle; RVOT – right ventricular outflow tract; PA – pulmonary artery; LA –left atrium.

Figure 1: A. 2-D ECHO presentation of DChRV – short axis, the arrows show the location of RV intracavitary obstruciton, the asterisk shows the place of maximal velocity (pressure gradient), B. Color Doppler presentation, tricuspidal insufficiency and pronounced turbulence after RV-obstruction (asterisk) in the direction of RVOT and the pulmonary artery (arrow), C. Intracavitary RV-gradient higher than 90 mmHg (CW Doppler).

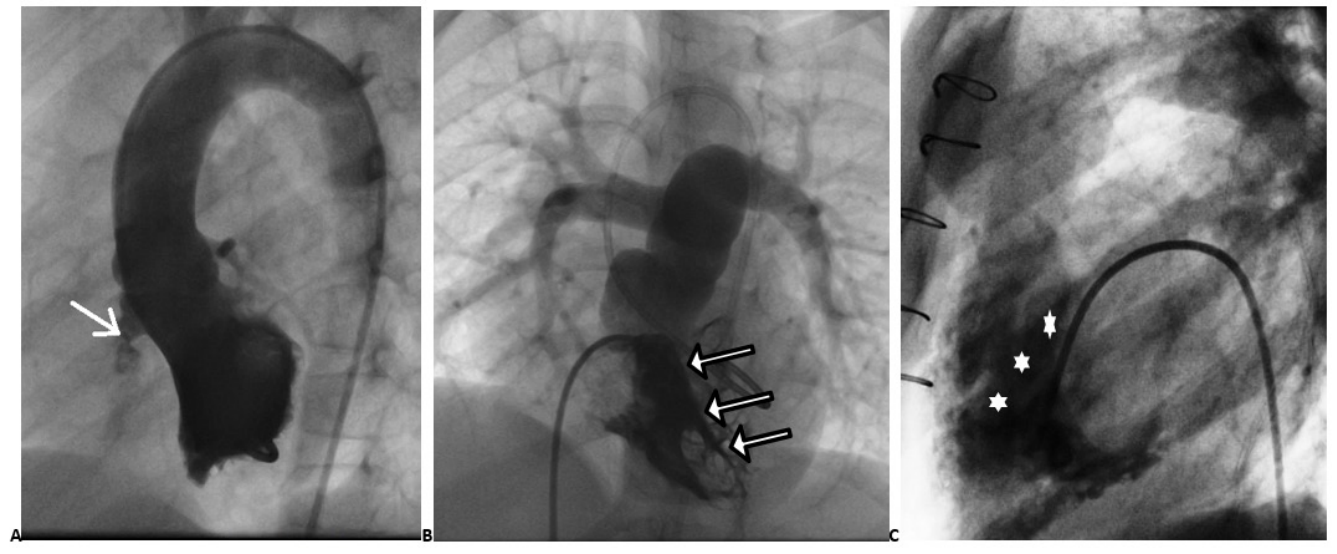

Figure 2:

A. Left ventriculography- small subaortic (supracristal) VSD which is the probable cause of the double chambered right ventricle (arrow) – communication toward the distal part of right ventricle.

B. Right ventriculography (anteroposterior projection – arrows show location of the right ventricular band),

C. Right ventriculography (lateral projection) – the asterisks show the place of intracavitary right ventricular rearrangement.

At the time of diagnosis of DchRV, three children had poor exercise tolerance, while two were asymptomatic. Two children (patients 2 and 4) had a peri membranous VSD, i.e. connected to the proximal cavity with high pressure, so the trans ventricular gradient was low. Two children (patients 3 and 5) had a VSD that was connected to the distal cavity (supra-crystal, doubly committed), with a high gradient in the right intraventricular cavities (mean value 73.33±5.77 mmHg). The youngest girl had two VSDs; one connected to the proximal and one to the distal cavity (patient 1). Two patients initially had additional stenoses at the outlet of the right ventricle in addition to the VSD; patient 2 had pulmonary valve stenosis (gradient 70 mmHg), and patient 5 had infundibular and valve stenosis (gradient 90 mmHg). In the latter two children, an operation was performed with the aim of treating the stenosis at the exit of the pulmonary artery from the RV, and the VSD was also closed. In one girl, the associated defects were an anomalous exit of the right subclavian artery from the descending aorta (a. lusoria), mild aortic valve insufficiency, and a visible developing subaortic membrane, without a pressure gradient (patient 3) (Table 1).

The operative procedure for resection of hypertrophic muscle bundles was performed at a mean age of 6.56 ± 3.23 years, and the mean gradient of intracavitary right ventricular pressure was 70.00 ± 15.71 mmHg (minimum 50 mmHg, maximum 90 mmHg). In all patients, simultaneously with the resection of the aberrant and hypertrophic muscle fibers that blocked the RV, the VSD was also closed. In two patients with obstructive fibbers and VSD, access was done through the RV, and in one girl through the right atrium. There were no intraoperative complications. After the surgical procedures, the patients were monitored by transthoracic ultrasound. The follow-up time was between 22 and 30 months (mean 24.33±3.51 months). During this period, complications of the surgical procedure were observed only in the boy who underwent the trans ventricular surgical approach. During continuous ECG monitoring, unstable ventricular tachycardia was recorded on several occasions, which stopped after the introduction of an antiarrhythmic drug (propafenone). In the same boy, a coronary fistula between the right coronary artery and the RV without hemodynamic significance was observed postoperatively, as well as a residual VSD that became hemodynamically significant after resection of the obstructive fibbers. The VSD was closed by reoperation. Currently, none of our patients complain of significant complications (Table 2).

Table 2: Results of surgical treatment in our patients with double chambered right ventricle.

Patient	Surgical op. due to DChRV	Surgical approach	Age at operation	Residual gradient in RV	Postoperative findings	Postsurgical complications	Arrhythmias	Follow-up	Recurrence of obstruction	Symptoms after operation
1 (BE)	VSD closure and obstructive band resection	Right ventriculotomy	2 yr 7 mth	20 mmHg	VSD closed re-sidual gradient 20 mmHg	None	None	26 mth	None	None
2 (MK)	VSD closure (patch) and obstructive band resection	Right ventriculotomy	5 yr 3 mth	No	Residual VSD , PV dysplasia, MPA hypoplasia	Coronary fistula LCA-DV without hemodynamic significance	Nonsustained VT	30 mth	None	None
3 (SZ)	VSD closure and obstructive band resection	Transtricuspid access	5 yr 0 mth	20 mmHg	Minimal AI, subaortic membrane without gradient	None	None	20 mth	None	None
4 (SA)	Waits for surgical treatment									
5 (II)	Waits for surgical treatment									

Abbreviations: AI – aortic insufficiency; DCRV – double chambered right ventricle; RV – right ventricle; yr- year; LCA – left coronary artery; mth– month; op- operation; PV- pulmonary valve; MPA- main pulmonary artery; VSD – ventricular septal defect; VT- ventricular tachycardia.

Discussion

This is a relatively rare entity whose incidence increases with age, as it is likely a progressive cardiac lesion. The typical age of diagnosis of DChRV is early childhood, although fetuses with DChRV and adult patients have also been described [6,18]. Our patients were between 2 and 11 years of age. All had an associated VSD, which is consistent with data from the literature, where VSD is found in between 63% and 96% of cases [6,15,17]. The high percentage of associated VSD in our patients is not surprising, since these are relatively young children, and it is likely that with age, part of the VSD is surgically (rarely spontaneously) closed and is no longer visible at a later diagnosis of DChRV. This primarily applies to supra-crystal VSD [19]. The cause of DChRV is unknown, but it is believed to be partly due to localized growth of trabeculated myocardium during early development. Some authors believe that the right ventricular division and obstruction represent incomplete incorporation of the primitive bulbus of the heart into the right ventricle, and this is related to the interpretation of the evolution of this rare defect in intrauterine findings. The irregular expansion of the bulb ventricular junction results in incomplete fusion of the elements of the endocardial cushions and the bulbus, which close the upper part of the ventricular septum, which could partly explain the frequent association of VSD with DChRV [10].

In our opinion, this theory has no clear scientific basis, since almost all patients have small defects that belong to flow disorders, and are not associated with membranous VSD, or with a possible etiopathogenetic factor belonging to Cono truncal anomalies (see later in the discussion). It is possible that the high trans ventricular gradient of the strong jet causes hypertrophy of the trabecular muscle of the right ventricle. Therefore, it is necessary to periodically monitor patients with VSD even after its spontaneous or surgical closure, especially if there is a residual (small) VSD that surgeons do not except for reoperation [1]. So far, no difference in incidence between the sexes has been observed, although in our study, girls predominate (4:1).

In two of our children, the VSD was peri membranous, in one girl, peri membranous with subaortic extension, while in one patient a small subaortic supracrustal VSD without hemodynamic significance (double committed) was found, but with a high trans ventricular gradient. We must emphasize here that pediatrics cardiologists too often describe peri membranous defects with possible "subaortic extension", which is probably incorrect. Namely, subaortic VSD is always membranous and belongs to a disorder of septo-arterial continuity, in which pulmonary hypertension develops and pressure equalization in the ventricles gradually occurs. The data to date also show the highest frequency of peri membranous VSD among defects associated with DChRV, while the percentage of supracrustal defects is significantly lower (about 1%). In a smaller percentage, the association of muscular VSD can also be found in the literature, although its localization is not always indicated (apical, trabecular multiply "Swiss cheese", central muscular) [9,15,17,19,20]. In one of our patients, remodeling occurred after a previously properly closed VSD (patient 5). In a series of patients from 2007 [19], most VSDs were located proximal to the obstructive lesion and were thus connected to a cavity with high intracavitary pressure. In our case, the relationship between the connection of VSDs with the distal and proximal cavities is somewhat different, or equal. When the VSD connects the left ventricle to the proximal part of the right ventricle (in front of the obstructive lesion), its pathophysiological acts as a tetralogy of Fallot or, better said, as a "Fallotised VSD", without a pressure gradient between the left ventricle (LV) and the RV (which may raise suspicion of pulmonary hypertension). However, when it connects the left ventricle to the distal part of the right ventricle (behind the obstructive lesion), it acts as an isolated VSD without pulmonary hypertension [21]. It is important to emphasize here a term that was too often mentioned in previous generations but was misinterpreted. Namely, TF always has infundibular stenosis because of migration of the neuroectodermal epithelium into the Cono truncal base for the heart.

Therefore, during TF surgery, surgeons are required to mainly remove the infundibular stenosis and reduce the gradient on the possibly additionally stenotic pulmonary valve (but not to completely remove it due to the possible late development of severe pulmonary insufficiency). If, however, surgeons (and pediatrics cardiologists) list sub pulmonary stenosis as part of the TF, the surgeon does not have to see the deep sub pulmonary stenosis, in fact an obstructive lesion due to a septate ventricle, and can only close the residual VSD. This creates a "vtium artis" that can end in an undesirable outcome. We did not find a consistent association between VSD placement and symptoms in our children, possibly because large flows were not present, regardless of the severity of the obstructive lesion that was baffle the right ventricle. This data speaks even more in favor of the need for children with small left-right flow at the level of the ventricle to be permanently monitored, just like children whose VSD had previously been properly closed by cardiosurgical surgery.

In addition to VSD, three of our patients also had other associated heart defects. Two of them initially had more distal obstruction of the right ventricular outlet (infundibular or valvular), and one girl had mild aortic insufficiency with the development of a subaortic ridge (membrane) and the exit of the right subclavian artery from the descending aorta (arteria lusoria). Multiple obstructions of the outlet part of the right ventricle are relatively often associated with DChRV, as well as changes in the aortic valve, subaortic ridge or membrane (in about 15% of cases). Pathological turbulent flow through the distal obstruction of the outflow tract of the right ventricle can also induce hypertrophic changes on the trabeculae of the supraventricular crest [1]. Compared to simple VSD, the incidence of aortic valve prolapse in DChRV is quite high. It is considered that the negative pressure caused by blood turbulence at the level of the RV outflow tract could be associated with prolapse of the non-coronary aortic cusp. Therefore, in patients with DChRV, it is important to evaluate

both the aortic valve and the subaortic region due to the increased risk of subaortic ridge formation [6,15]. The changes observed in our girl with supra-crystal VSD are listed. It should not be forgotten that hemodynamically insignificant L-D flow in supracrystall VSD is recommended to be closed by cardio surgery precisely because of the development of aortic insufficiency due to aortic valve prolapse (most often non-coronary cusp).

All our patients had a high gradient between the proximal and distal parts of the right ventricle and surgery was indicated, even though some patients did not have any symptoms. The symptoms that our patients complained of were dyspnea and decreased exercise tolerance. Less commonly described are poor weight gain, cyanosis, fatigue, chest pain, palpitations, loss of consciousness, symptoms of heart failure, and infective endocarditis [6,13,15,16]. All our patients were diagnosed preoperatively. Suspicion of DChRV was established by ultrasound based on the findings of obstruction and gradient in the right ventricle subinfundibularly, but the diagnosis was also confirmed by cardiac catheterization. This is an error that is not always easily visible by ultrasound, and anomalous muscle bundles are difficult to visualize in the four-chamber view. It is not always easy to visualize and accurately assess the right ventricular outflow tract due to its retrosternal location and because the direction of flow through the chambered right ventricle is usually parallel to the ultrasound probe in the parasternal view [22]. For this reason, right ventricular remodeling is sometimes only discovered during cardiac surgery due to associated heart defects. Therefore, if a gradient remains after surgical resolution of the obstruction at the level of the right ventricular outflow tract, associated DChRV should be suspected [15]. The condition is, of course, easier to recognize if the entity described here is considered.

The indications for surgical treatment of asymptomatic patients are still not clearly defined but Said, et al. [15] based on the results of the treatment of 61 patients advise surgical treatment in patients with symptoms, associated heart defects requiring surgery, aortic insufficiency, high flow, and significant obstruction at the level of the right ventricle. Due to the likelihood of developing symptoms based on the progressive course of the disease [8], modern guidelines now advise surgery even in asymptomatic patients with a relatively low intraventricular gradient (< 64 mmHg) [14]. In non-operated patients, symptoms usually appear in middle adulthood (mean age 40 years), but they can also appear in early childhood [6]. However, if there is no significant associated defect, the patient can sometimes be regularly monitored clinically and echocardiographic ally until the pressure gradient does not exceed 40 mmHg and the obstruction does not show progression [23]. All our patients had a significant pressure gradient at the level of the right ventricle (> 50 mmHg), and some of them already had symptoms, while others did not have any problems despite the high intraventricular gradient (up to 90 mmHg). All of them tolerated the cardiac surgery well as expected, and there were no serious intraoperative or postoperative complications.

In a boy who was treated surgically through the right ventricle (patient 2), unstable ventricular tachycardias were observed postoperatively, which subsided on antiarrhythmic medication (Propafenone). Although it carries a certain risk of developing arrhythmias, the right ventricular approach may be advantageous in severe obstruction because it allows for a better assessment of all elements of the obstruction and adequate visualization of the edges of the VSD [7]. It is important to emphasize that serious right ventricular dysfunction and lethal ventricular arrhythmias after surgical treatment of DChRV are very rare, in contrast to arrhythmias after surgical correction of ToF [6,15,24]. This is understandable because the infundibulum of the right ventricle is a fertile ground for the development of arrhythmias, and in this case, it is a sub infundibular stenosis. According to numerous reports in recent years, the infundibulum is the source of most malignant arrhythmias. This opinion is also supported by the fact that the infundibulum is part of the migration process of neuroectoderm into the mesenchymal basis for the heart and is located as the only part of the neuroectoderm in the outflow tract of the right ventricle. This is also in line with the latest research according to which some cardiac elements originate from the central nervous system. If, therefore, the DChRV were a "Falotised VSD", surgical removal of thickened sub-infundibular stenosis would have frequent malignant arrhythmias, which is a regular occurrence in TF surgery, and malignant arrhythmias have not been recorded in surgical removal of the DChRV.

Extensive research by Taiwanese cardiologists has documented the arrhythmogenesis of the right ventricular outflow tract. They found that the right ventricular outflow tract (RVOT) is a major cause of ventricular arrhythmias, including premature ventricular contractions, idiopathic ventricular arrhythmias, Brugada syndrome, torsade de pointes, long QT syndrome, and arrhythmogenic right ventricular cardiomyopathy. The RVOT has a diverse developmental origin and cellular characteristics, and a complex myocardial architecture with high wall frictional stress (adhesion), which may lead to its high susceptibility to arrhythmogenesis. RVOT myocytes are sensitive to intracellular sodium and calcium overload due to modulation of calcium-handling proteins, increased CaMKII activity, phosphorylation of ryanodine receptors, and higher levels of cAMP activated by predisposing factors or pathological conditions. Downregulation of Cx43 and Scn5a expression can lead to electrical uncoupling in the RVOT. The purpose of this review is to update the current understanding of the cellular and molecular mechanisms of RVOT arrhythmogenesis [25].

These studies certainly exclude from consideration the assumption that DChRV occurs already intrauterine due to disturbances in the arrangement of tissues of the infundibulum. In addition, we do not find arrhythmogenesis there. Numerous investigators have reported severe arrhythmogenic episodes or sudden death after TF surgery, even many years after surgery [26]. This is in accordance with our experience with arrhythmogenic right ventricular cardiomyopathy,

which also refers to the occurrence of severe and/or fatal arrhythmias in families who inherit these cardiomyopathies, more often after childhood and in adolescence. The same happens with Naxos Island disease and Carwajal syndrome [27]. From our experience, arrhythmogenic right ventricular dysplasia shows arrhythmias even at a young age group. In any case, here too, RVOT dysplasia and changes in it are a cause for concern [28]. From these experiences and reports, we can consider that DChRV is not a disorder of Cono truncus path morphology but a consequence of the proliferation of the right ventricular musculature subinfundibularly, so that this tissue does not have the properties of neuroectoderm.

Migration of neuroectoderm (more precisely, neural crest cells) into the mesenchymal base of the heart is a key embryonic process for the formation of the outflow tract of the heart. This process takes place during the fourth week of embryonic development, and disorders of this migration lead to congenital heart defects. In both right ventricular and right atrial approaches, it is important to pay attention to preserving tricuspid valve function [11,15]. In the literature, there are rare cases of early postoperative death after surgical correction of DChRV, most often due to low cardiac output. Serious late complications include heart failure, myocardial infarction, and sudden death. A small percentage of patients required a permanent pacemaker due to postoperative complete atrioventricular block [6,15]. However, most of the serious morbidity and mortality associated with DChRV was rather the result of misdiagnosis, resulting in postoperative deterioration rather than cure. The most common residual problems in surgically treated patients with DChRV are mild residual right ventricular outflow tract obstruction, hemodynamically insignificant residual VSD, and tricuspid and aortic insufficiency [7,29-32].

The quantification of L-D flow is presented in our paper according to the findings of radioangioscintigraphy, considering its superiority over other methods for assessing the size of L-D flow [32], and PVR was calculated based on Fick's principle (all listed in Table 1). In the Maltz-Treves formula program, the existence of L-D flow with values below 10% is not taken into account in the radioangioscintigraphic analysis, considering the possibility of physiological L-D flow, so in a state with L-D flow below 10% (which is practically "absent"), it is still possible to demonstrate a small L-D flow angiocardiographic ally (Figure 2A). Therefore, the defect is so small that it can only be demonstrated selectively by left ventriculography, and it is below the limit of detection for oximetry, and even for radioangioscintigraphy. However, such a defect can certainly be the reason for the development of intracavitary right ventricular septal defect (patients 1 and 3) [33].

All our children tolerated the cardiac surgery well with the expected recovery time. Apart from the short-term ventricular arrhythmias in one boy, the procedures were performed without early complications, with a residual gradient at the septal defect site of less than or equal to 20 mmHg. However, the example of our patient (patient 2) showed that it is important to close the associated VSD during the procedure, since resolving the obstruction changes hemodynamic and an initially low flow rate can become hemodynamically significant postoperatively, especially in proximally located defects. In this case, removal of the obstructive fibbers abruptly increases the pressure gradient and thus the flow rate through the VSD. During the follow-up period of our patients, there were no serious late complications of septal defect resection surgery. Serious postoperative complications are very rare, especially in the last two decades, and excellent postoperative survival and quality of life are expected [15,17]. In a large series of 61 patients described by Said, et al. [15], none required reoperation due to recurrence of obstruction for at least 4 years, while some patients were followed for several decades. Similar results were obtained in a series of 38 patients by Amano, et al. [17]. Surgical correction of DChRV results in excellent long-term functional and hemodynamic results with complete resolution of the right ventricular obstructive lesion.

Conclusion

It is important to consider the possibility of developing DChRV even after successful VSD closure and to continue to monitor such patients at longer intervals. Right ventricular remodeling is probably caused by the presence of a VSD, regardless of size and location, and can develop in primary, residual VSD, and after successful VSD closure. It is important to close the VSD simultaneously with resection of the obstructive fibers, since initially low flow can become hemodynamically significant postoperatively. After surgical resolution of DChRV, long-term follow-up is necessary due to the possibility of recurrence of the septation, the appearance of a subaortic membrane, and/or aortic valve insufficiency. Surgical removal of hypertrophic and aberrant tissue is an adequate form of treatment with relatively rare serious complications, which, given the expected progressive course of the disease, justifies resorting to surgical treatment in cases of significant DChRV obstruction and in the absence of symptoms.

References

1. Loukas M, Housman B, Blaak C, Kralovic S, Tubbs RS, et al. (2013) Double-chambered right ventricle: a review. Cardiovasc Pathol 22(6): 417-23.
2. Restivo A, Cameron AH, Anderson RH, Allwork SP (1984) Divided right ventricle: a review of its anatomical varieties. Pediatr Cardiol 5(3): 197-204.
3. Wang JK, Wu MH, Chang CI, Chiu IS, Chu SH, et al. (1996) Malalignment-type ventricular septal defect in double-chambered right ventricle. Am J Cardiol 77(10): 839-842.
4. Bashore TM (2007) Adult congenital heart disease: right ventricular outflow tract lesions. Circulation 115(14): 1933-1947.
5. Forster JW, Humphries JO (1971) Right ventricular anomalous muscle bundle. Clinical and laboratory presentation and natural history. Circulation 43(1): 115-127.
6. Kahr PC, Alonso Gonzalez R, Kempny A, Orwat S, Uebing A, et al. (2014) Long-term natural history and postoperative outcome of double-chambered right ventricle-experience from two tertiary adult congenital heart centers and review of the literature. Int J Cardiol 174(3): 662-668.

7. Hachiro Y, Takagi N, Koyanagi T, Morikawa M, Abe T, et al. (2001) Repair of double-chambered right ventricle: surgical results and long-term follow-up. Ann Thorac Surg 72(5): 1520-1522.
8. Oliver JM, Garrido A, Gonzalez A, Benito F, Mateos M, et al. (2003) Rapid progression of midventricular obstruction in adults with double-chambered right ventricle. J Thorac Cardiovasc Surg 126(3): 711-717.
9. Hoffman P, Wojcik AW, Rozanski J, Siudalska H, Jakubowska E, et al. (2004) The role of echocardiography in diagnosing double chambered right ventricle in adults. Heart 90(7): 789-793.
10. Animasahun BA, Ekure EN, Njokanma OF (2011) Double-chambered right ventricle: an uncommon congenital heart disease. Case report and literature review. Cardiovasc J Afr 22(5): 274-277.
11. Alva C, Ho SY, Lincoln CR, Rigby ML, Wright A, et al. (1999) The nature of the obstructive muscular bundles in double-chambered right ventricle. J Thorac Cardiovasc Surg 117(6): 1180-1189.
12. Fellows KE, Martin EC, Rosenthal A (1977) Angiocardiography of obstructing muscular bands of the right ventricle. AJR Am J Roentgenol 128(2): 249-256.
13. Nagashima M, Tomino T, Satoh H, Nakata T, Ohtani T, et al. (2005) Double-chambered right ventricle in adulthood. Asian Caradiovasc Thorac Ann 13(2): 127-130.
14. Baumgartner H, Bonhoeffer P, De Groot NM, de Haan F, Deanfield JE, et al. (2010) ESC Guidelines for the management of grown-up congenital heart disease (new version 2010). Eur Heart J 31(23): 2915-2957.
15. Said SM, Burkhart HM, Dearani JA, OLeary PW, Ammash NM, et al. (2012) Outcomes of surgical repair of double-chambered right ventricle. Ann Thorac Surg 93(1): 197-200.
16. McElhinney DB, Chatterjee KM, Reddy VM (2000) Double-chambered right ventricle presenting in adulthood. Ann Thorac Surg 70(1): 124-127.
17. Amano M, Izumi C, Hayama Y, Onishi N, Tamaki Y, et al. (2015) Surgical Outcomes and Postoperative Prognosis Beyond 10 Years for Double-Chambered Right Ventricle. Am J Cardiol 116(9): 1431-1435.
18. Marton T, Hajdu J, Papp Z (2001) A rare case of non-immune hydrops fetalis: double-chambered right ventricle. A case report. Fetal Diagn Ther 16(4): 251-253.
19. Hubail ZJ, Ramaciotti C (2007) Spatial relationship between the ventricular septal defect and the anomalous muscle bundle in a double-chambered right ventricle. Congenit Heart Dis 2(6): 421-423.
20. Wong PC, Sanders SP, Jonas RA, Colan SD, Parness IA, et al. (1991) Pulmonary valve-moderator band distance and association with development of double-chambered right ventricle. Am J Cardiol 68(17): 1681-1686.
21. Pongiglione G, Freedom RM, Cook D, Rowe RD (1982) Mechanism of acquired right ventricular outflow tract obstruction in patients with ventricular septal defect: an angiocardiographic study. Am J Cardiol 50(4): 776-780.
22. Choi YJ, Park SW (2010) Characteristics of double-chambered right ventricle in adult patients. Korean J Intern Med 25(2): 147-153.
23. Cil E, Saraclar M, Ozkutlu S, Ozme S, Bilgic A, et al. (1995) Double-chambered right ventricle: experience with 52 cases. Int J Cardiol 50(1): 19-29.
24. Harrison DA, Harris L, Siu SC, MacLoghlin CJ, Connelly MS, et al. (1997) Sustained ventricular tachycardia in adult patients late after repair of tetralogy of Fallot. J Am Coll Cardiol 30(5): 1368-1373.
25. Yen Yu Lu, YaChang Chen, YungKou Lin, ShihAnn Chen, Yi-Jen Chen, et al. (2023) Electrical and Structural Insight into Right Ventricular outflow Tract Arrhythmogenesis. International Journal of Molecxular Sciences 24(14): 11795.
26. Gatzoulis MA, Balaji S, Webber SA (2000) Čimbenici rizika za aritmiju i iznenadnu srčanu smrt nakon operac ije tetralogije Fallot: multicentrična studija. Lancet 356: 975-981.
27. Malčić I, BUljević B (2017) Arrhythmogenic right ventricular cardiomyopathy, Naxos Islad disease and Carvajal Syndrome. Central Eur J Paed 13(2): 93-106.
28. Malčić I, Kniewald H, Tokić Pivac V, Jelašić D, Buljević B, et al. (2016) Right Ventricular arrhythmogenic cardiomyopathy -Have we avoided family tragedy by applying contemporary diagnostic and treatment approach. Liječ Vjesn 138: 339-344.
29. Telagh R, Alexi Meskishvili V, Hetzer R, Lange PE, Berger F, et al. (2008) Initial clinical manifestations and mid- and long-term results after surgical repair of double-chambered right ventricle in children and adults. Cardiol Young 18(3): 268-274.
30. Rowland TW, Rosenthal A, Castaneda AR (1975) Double-chamber right ventricle: experience with 17 cases. Am Heart J 89(4): 455-462.
31. Ibrahim T, Dennig K, Schwaiger M, Schomig A (2002) Images in cardiovascular medicine. Assessment of double chamber right ventricle by magnetic resonance imaging. Circulation. 105(22): 2692-2693.
32. Kveselis D, Rosenthal A, Ferguson P, Behrendt D, Sloan H, et al. (1984) Long-term prognosis after repair of double-chamber right ventricle with ventricular septal defect. Am J Cardiol 54(10): 1292-1295.
33. Malčić I, Senečić I, Težak S, Ivančević D, Kniewald H (2000) Radioangioscintigraphy and Doppler Echocardiography in the Quantification of Left-to- Right Shunt. Pediatr Cardiol 21: 240-243.

ISSN: 2574-1241

DOI: 10.26717/BJSTR.2026.67.010483

Ivan Malčić . Biomed J Sci & Tech Res

This work is licensed under Creative *Commons* Attribution 4.0 License

Submission Link: https://biomedres.us/submit-manuscript.php



Assets of Publishing with us

- Global archiving of articles
- Immediate, unrestricted online access
- Rigorous Peer Review Process
- Authors Retain Copyrights
- Unique DOI for all articles

https://biomedres.us/