

# A Case Report of Ruptured Sebaceous cyst

**Priya R Sheth\***

Associate Professor, Department of Homoeopathic Repertory, B.V.D.U.H.M.C, Pune, India

\*Corresponding author: Priya R Sheth, Associate Professor, Department of Homoeopathic Repertory, B.V.D.U.H.M.C, Pune, India

## ARTICLE INFO

**Received:** 📅 April 06, 2026

**Published:** 📅 April 29, 2026

**Citation:** Priya R Sheth. A Case Report of Ruptured Sebaceous cyst. Biomed J Sci & Tech Res 65(3)-2026. BJSTR. MS.ID.010194.

## Introduction

A cyst is a sac like pocket of membranous tissue that contains fluid, air or other substances. Cyst can grow almost anywhere in our body or under our skin. There are many types of cyst and mostly they are benign or non-cancerous. It is differentiated from tumor by being tender and soft.

## Case Presentation

A 50 yrs. old male came to Bharati Vidyapeeth Homoeopathic Hospital O.P.D ON 11/10/2021 with complaints of painful swelling with yellowish, bloody discharge on the nape of neck. He had throbbing type of pain < touch, pressure, movement since 2yrs.

The swelling was approx. 2cm in size, reddish, tender, soft, movable and discharging pus.

## Past History

The patient was under allopathic treatment for 2 yrs., with no relief in complaints and was advised surgical intervention.

## Family History

Mother – Diabetic Father – Hypertensive

Siblings – Brother died due to MI, 4yrs ago.

## Personal History

- **Appetite** - Eats only 2 small meals /day.
- **Thirst** – 2-3 liters /day.
- **Craving** – Spicy+, mutton++, and seafood+++
- **Aversion** – Soybean, (raw onion as it causes cold), alcohol.

- **Stool** – Regular and satisfactory 1 time / day.
- **Urine** – Regular 2-4 times /day, 0-1 / night.
- **Perspiration** – Only on exertion, on face.
- **Sleep** – Sound and refreshing (6- 7 hours), one covering required, requires fanning.
- **Dreams:** Nothing specific.
- **Thermals:** Hot patient.
- **Mind:** When angry, keeps quiet, doesn't express.

Likes to explore new places, likes travelling.

Has faith in Homoeopathic medicines, hence came for the treatment.

## General Physical Examination

1. Patient is conscious and sitting comfortably in chair.
2. Appearance – Moderately flabby built and well nourished, dark in color.
3. Oral hygiene – good
4. Pallor, cyanosis, lymphedema, icterus – not detected.

## Vital Signs

- **Temp:** Afebrile
- **Pulse:** 72/min
- **BP:** 130/90mmHg
- **RR:** 19/min

## Systemic Examination

- R.S – Air entry bilaterally equal.
- C.V.S – S1S2 heard, no murmurs.
- G.I.T – No tenderness, abdomen soft, umbilicus centrally located.
- C.N.S – conscious, well oriented.

## Local Examination

- **Appearance** – The cyst had smooth ulcerated surface, with centrally raised edges and irregular margin.
- **Color** – The color of the cyst was blackish with yellowish bloody discharge.
- **Consistency** – The cyst was firm, soft in consistency with pus filled pockets.
- **Pulsatility** – The cyst showed no pulsatility.
- Compressibility and reducibility test was negative.
- As the cyst was of discharging pus, fluctuation and fluid thrill test was negative.
- **Mobility** – The cyst was movable on the underlying tissue.

## Rubrics

1. **(Murphy) Neck** - Eruptions
2. **(Murphy) Pain** - Neck
3. **(Murphy) Generals** - Throbbing Sensation
4. **(Murphy) Generals** – Discharges, From Ulcers - Bloody

5. **(Murphy) Ulcers, General** – Painful
6. **(Murphy) Ulcers, General** – Fistulous

## Repertorisation

(Image 1).

1. Prescription 11/10/2021 –
  - Belladonna 1M 4 pills 2 hourly for 2 days.
  - Causticum 30 4 pills 4 times a day for 7 days Figure 1.
2. Follow up (1) 13/ 10/2021-
  - Only slight relief in pain, hence Belladonna 10M 2 doses were given, one stat and one at night.
3. Follow up (2) 19/10/2021-Figure 2 and Figure 3
  - Throbbing pain reduced by 90%.
  - No new complaints.
  - Swelling reduced in size with no discharge.
  - Medicine prescribed – Silicea 6x 2 tabs five times per day/7 days
  - Calendula ointment for local application was given.
4. Follow up 24/11/2021 Figure 4 and Figure 5
  - Complaints of throbbing pain reduced completely and discharged stopped.
  - Ulcer healed leaving no scar on the site of lesion.
  - Patient was overall better with no complaints

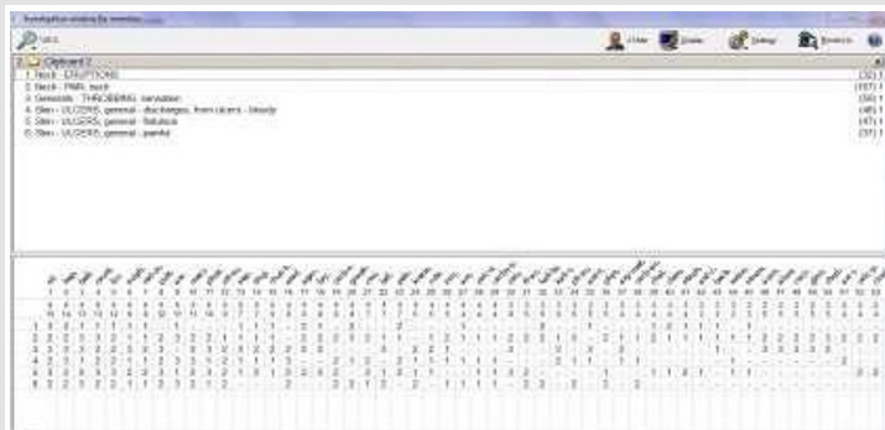


Image 1.

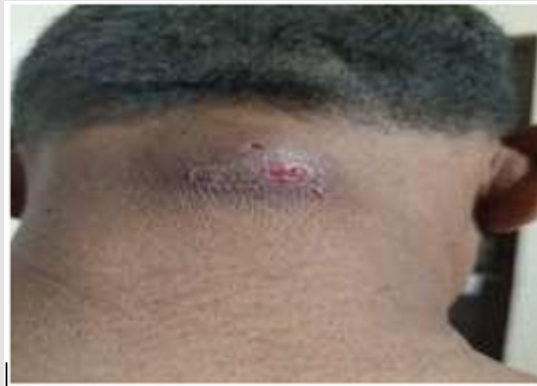

Figure 1.

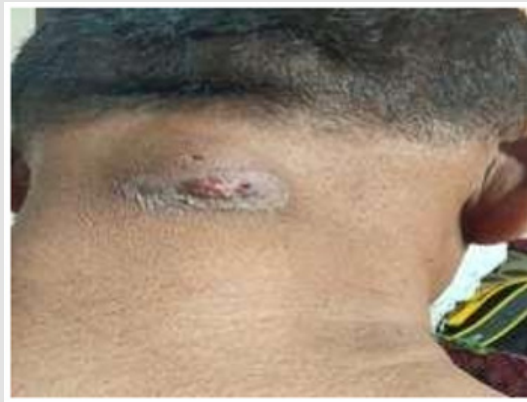

Figure 2.

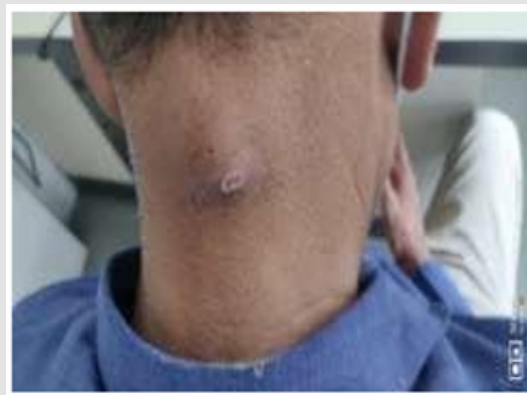

Figure 3.

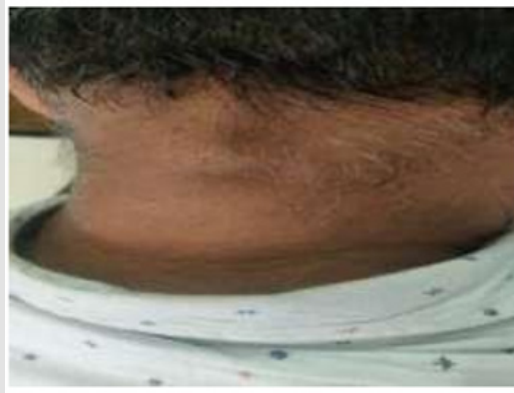

Figure 4.

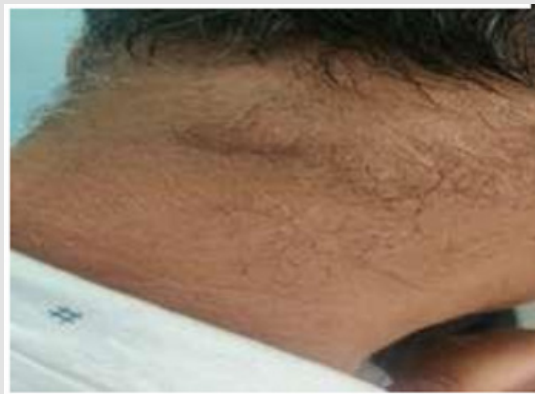

Figure 5.

### Discussion of the Case

A Case of Cystic ulcerative swelling with yellowish bloody discharge, presented with throbbing pain in the nape of neck. Belladonna 1M was prescribed repeatedly till the pain was reduced followed by Belladonna 10M 2 doses after which the pain stopped and the swelling was also reduced. Causticum was given keeping in mind its sphere of action on nape of neck with burning, rawness and soreness as its characteristic symptoms. Silicea was prescribed after which the ulcer was healed completely with no discharge and swelling. Calendula was given as a local application. All the above prescriptions were based on

presenting complaints and the case was resolved keeping in mind the local pathological symptoms.

### References

1. Davidson Medicine Book.
2. Homoeopathic Medical Repertory by Dr Robin Murphy.
3. Clinical Surgery by S Das.
4. Boericke Materia Medica.
5. Organon Of Medicine by Dr S Hahnemann.

ISSN: 2574-1241

DOI: 10.26717/BJSTR.2026.65.010194

Priya R Sheth. Biomed J Sci & Tech Res



This work is licensed under Creative Commons Attribution 4.0 License

Submission Link: <https://biomedres.us/submit-manuscript.php>



### Assets of Publishing with us

- Global archiving of articles
- Immediate, unrestricted online access
- Rigorous Peer Review Process
- Authors Retain Copyrights
- Unique DOI for all articles

<https://biomedres.us/>