

# Bisalbuminemia – A Rare Diagnosis in Pediatrics

Miguel Gouveia<sup>1\*</sup>, Rita Carneiro Martins<sup>2</sup> and Miguel Costa<sup>3</sup>

<sup>1</sup>Family Medicine Resident, Family Health Unit Nordeste, Local Health Unit Entre Douro e Vouga, Santa Maria da Feira, Portugal

<sup>2</sup>Pediatric Resident, Department of Pediatrics, Local Health Unit Entre Douro e Vouga, Santa Maria da Feira, Portugal

<sup>3</sup>Pediatric Attending Physician, Department of Pediatrics, Local Health Unit Entre Douro e Vouga, Santa Maria da Feira, Portugal

\*Corresponding author: Miguel Gouveia, Family Medicine Resident, Family Health Unit Nordeste, Local Health Unit Entre Douro e Vouga, Santa Maria da Feira, Portugal

## ARTICLE INFO

**Received:** 📅 March 13, 2026


**Published:** 📅 March 25, 2026

**Citation:** Miguel Gouveia, Rita Carneiro Martins and Miguel Costa. Bisalbuminemia – A Rare Diagnosis in Pediatrics. Biomed J Sci & Tech Res 65(1)-2026. BJSTR. MS.ID.010148.

## ABSTRACT

This clinical case concerns a fifteen-year-old adolescent referred by her family doctor to the outpatient Pediatrics clinic due to fatigue symptoms evolving over six months. The patient has normal height and weight development and an unremarkable physical examination. A complete blood count and biochemical tests were requested as complementary studies, which revealed only an alteration in protein electrophoresis, indicating bisalbuminemia (Figure 1). Total albumin levels were within the reference range. A family study was requested to determine the etiology of the diagnosis (acquired or hereditary). There are a few cases described in literature, especially in the pediatric age and the future implications or consequences of the condition remain unclear. Thus, although the clinical significance of this pathology is uncertain, the diagnosis should be established and underlying disease excluded to ensure proper patient management.

**Keywords:** Bisalbuminemia; Hereditary Albumin Variant; Adolescent Case Report; Protein Electrophoresis; Incidental Diagnosis



**Figure 1:** Plasma protein electrophoresis showing two serum albumin peaks. [Adolescent/Patient].

## Introduction

Hereditary bisalbuminemia is a condition with few documented cases and is usually discovered incidentally, leading to further investigation of other family members. Plasma protein electrophoresis does not allow precise identification of which albumin peak corresponds to normal or modified albumin. However, this distinction has no clinical relevance.

## Patient Information

A 15-year-old female adolescent with no significant past medical history was followed by her family doctor for asthenia, sadness, emotional lability, and decreased appetite lasting approximately six months. The clinical picture was initially interpreted as a depressive episode. However, due to worsening fatigue, she was referred to the General Pediatrics clinic. No other associated symptoms or complaints were reported. She was not on any regular medication. No recent infectious events were noted. Growth and weight development were normal.

## Clinical Findings and Diagnostic Assessment

The physical examination was unremarkable. An analytical work-up was performed, including renal, thyroid, and liver function, iron

studies, total proteins, immunoglobulins, anti-transglutaminase IgA antibodies, and plasma protein electrophoresis. All test results were normal, except for the electrophoresis, which confirmed the presence of a bifid albumin peak, characteristic of bisalbuminemia, as shown in Figure 1. Plasma albumin concentration was within normal limits. After excluding secondary causes of the referring symptom (fatigue) and in the presence of other symptoms such as asthenia, sadness, emotional lability, and decreased appetite over approximately six months without apparent improvement, it is reasonable to attribute the symptomatology to a depressive condition.

## Therapeutic Intervention

No therapeutic intervention was necessary regarding the albumin alteration, as the diagnosis of bisalbuminemia has no clinical implications. Regarding the depressive symptoms, the patient was referred to psychotherapy sessions, with no pharmacological treatment initiated as the first-line approach.

## Follow-up and Outcomes

Given the patient's analytical results, plasma protein electrophoresis was requested for the adolescent's parents (to determine hereditary etiology), confirming the diagnosis in the mother (Figure 2). The father's electrophoresis was normal.

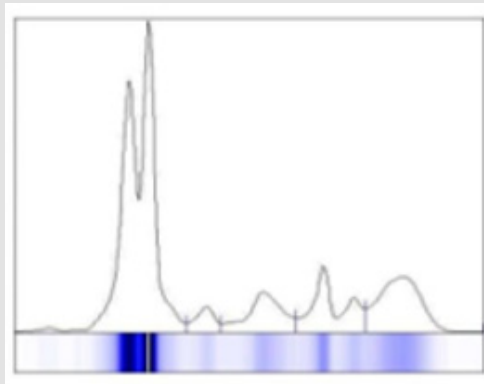


Figure 2: Plasma protein electrophoresis showing two serum albumin peaks. [Mother].

## Discussion

Bisalbuminemia is a qualitative variation of albumin occurring when an individual presents with two types of serum albumin: normal plasma albumin and a modified form. This alteration may be of acquired (transient) or hereditary (permanent) etiology [1]. Acquired bisalbuminemia has been described in association with drug-induced effects (e.g., high doses of beta-lactam antibiotics), acute pancreatitis and rupture of pancreatic pseudocysts, multiple myeloma, sarcoidosis, chronic kidney disease, and Waldenström macroglobulinemia [2, 3]. Hereditary bisalbuminemia is an albumin variant with a prevalence of 1:1,000 to 1:10,000, transmitted in an autosomal codomi-

nant manner [2,3], and is usually discovered incidentally, prompting further family investigation. Plasma protein electrophoresis does not allow precise identification of which peak corresponds to normal or modified albumin, though this distinction has no clinical significance. Although hereditary bisalbuminemia is not associated with clinical symptoms, one type of hereditary albumin variant has clinical relevance and should be considered. Familial dysalbuminemic hyperthyroxinemia (FDH), inherited in an autosomal dominant pattern, is characterized by disproportionately elevated total serum thyroxine (T<sub>4</sub>) compared to triiodothyronine (T<sub>3</sub>). This condition is caused by a human serum albumin (HSA) variant with relatively higher binding

affinity for T4 than for T3 [4]. This disease is associated with symptoms of hyperthyroidism such as palpitations, weight loss, tremors, and anxiety [5]. Albumin variations, whether acquired or hereditary, should always be on clinicians' radar, as they may represent a laboratory alteration indicating other underlying diagnoses.

### Acknowledgment

This clinical case was prepared with the assistance of the CARE guidelines for case reports. The authors belong to the Entre Douro e Vouga Local Health Unit, where the consultations and the patient's clinical investigation were carried out. This work was only possible due to the Pediatrics rotation within the Medical Residency in General and Family Medicine, which brings together residents in General and Family Medicine with Pediatric specialists and residents.

ISSN: 2574-1241

DOI: 10.26717/BJSTR.2026.65.010148

Miguel Gouveia. Biomed J Sci & Tech Res



This work is licensed under Creative Commons Attribution 4.0 License

Submission Link: <https://biomedres.us/submit-manuscript.php>

### References

1. Joana Silva, Joana Ferreira, Mariana Silva, Miguel Costa (2021) CASO CLÍNICO BIOQUÍMICO. Nascer e Crescer - Birth and Growth Medical Journal 30(4): 249-251.
2. Chhabra S, Bansal F, Saikia B, Minz RW (2013) Bisalbuminemia: a rarely encountered protein anomaly. J Lab Physicians 5(2): 145-146.
3. Carla Garcez, Susana Carvalho (2017) Bisalbuminemia: A Rare Variant of Albumin. Acta Med Port 30(4): 330-333.
4. Av Ruskin TW, Juan CS, Weiss RE (2002) Familial dysalbuminemic hyperthyroxinemia: a rare example of albumin polymorphism and its rapid molecular diagnosis. J Pediatr Endocrinol Metab 15: 801-807.
5. Zhao L, Zhou Y, Huang F, He X, Mei G, et al. (2023) Clinical characteristics of familial dysalbuminemic hyperthyroxinemia in Chinese patients and comparison of free thyroxine in three immunoassay methods. Front Endocrinol (Lausanne) 14: 1102777.



### Assets of Publishing with us

- Global archiving of articles
- Immediate, unrestricted online access
- Rigorous Peer Review Process
- Authors Retain Copyrights
- Unique DOI for all articles

<https://biomedres.us/>