

# Prevalence and Correlation Between HbA1c Control and Duration of Diabetes with Blindness Due to Progression of Advanced Diabetic Retinopathy at Eye Department of Tobruk Medical Center in Tobruk-Libya

**Abdolmejed Fathy\***

Assistant Professor, Faculty of medicine, Tobruk university, Libya

\*Corresponding author: Abdolmejed Fathy, Assistant Professor, Faculty of medicine, Tobruk university, Libya

## ARTICLE INFO

**Received:** 📅 September 25, 2024

**Published:** 📅 October 15, 2024

**Citation:** Abdolmejed Fathy. Prevalence and Correlation Between HbA1c Control and Duration of Diabetes with Blindness Due to Progression of Advanced Diabetic Retinopathy at Eye Department of Tobruk Medical Center in Tobruk-Libya. Biomed J Sci & Tech Res 59(1)-2024. BJSTR.MS.ID.009244.

## ABSTRACT

A prospective cross-sectional study of diabetic patients registered at Eye department of Tobruk medical center in Tobruk-Libya between (01.06.2023 to 29.02.2024). Data was collected using self-administered questionnaire. Grading of DR was done by slit-lamp examination and Fundoscopy by ophthalmologist. Descriptive analysis included percentage and mean, median, and p-value by using SPSS 25. There were 85 diabetic patients, ages ranged between 30 and 90 years, with a mean of 58, the majority (97.6%) were Libyan nationality living in Tobruk (98.3 %). There were 86 females. that patients with duration of diabetes ranging between 11 and 15 years were at almost five-folded risk of developing DR compared to those with duration <10years. Most of advanced complicated diabetic retinopathy cases had diabetes more than fifteen years, and no advanced disease in the cases with duration less than 10 years. The patients with poor controlled blood sugar and HbA1c >9 throughout the disease were at almost five-folded risk of developing DR compared to those with moderate controlled diabetes cases were HbA1c between (7.5 -9), patient with poor control of diabetes HbA1c >9 was 25-folded risk of developing PRP than cases with good control HbA1c <7.5. The majority of advanced diabetic retinopathy cases were correlated with non-controlled diabetes mellitus HbA1c > 9%, were no advanced complication recorded in good controlled cases. The objective of this study to estimate the prevalence and identify the correlation between risk factors like age of patients, type of DM, duration, no control of diabetes mellitus patients with blindness due to progression of DR attending the Eye Department at Tobruk medical in Tobruk-Libya.

## Introduction

Diabetes mellitus is a chronic metabolic disease characterized by hyperglycemia/ hypoglycemia, damage to large blood vessels (macrovascular) like cardiovascular and cerebrovascular disease and damage in to the small blood vessels (microvascular) like nephropathy or retinopathy [1]. Diabetic retinopathy is one of the commonest microvascular complications of diabetes mellitus. Diabetic retinopathy (DR) is common cause of blindness among adults in the Western world [2]. Diabetic retinopathy in patients with type 1 (insulin dependent DM) more than with type 2 (insulin depending DM), and was found to be related to both severity of hyperglycemia and presence of other chronic diseases like hypertension [3]. Diabetic retinopathy

is usually detected in late stages, because of the lack of awareness in our country about the risk of the disease as well as poor motivation for regular health care, diabetic patients in our community only come for consultation after the disease has become symptomatic. (El-Bab 2012) Early detection of DM, good control blood sugar in blood and effective diabetes management with diet and exercise can significantly decrease progression of diabetic retinopathy [4].

Diabetic retinopathy is one of leading cause of blindness worldwide. Because prolong time and less control of blood sugar in blood damaging the retinal blood vessel. In early stages, diabetic retinopathy usually asymptomatic, this result of late diagnosis of DR and patients not come for consultation unless irreversible progressive stage

started progress with time to different stages if not managed early [5]. Several stages start from mild non proliferative DR with small microaneurysms of retinal blood vessels, to sever proliferative stages with growing of new fragile retinal blood vessels which can lead to advanced blindness leading problems like vitreous hemorrhage, macular ischemia and retinal detachment [6]. There are some treatment options which depending on severity of the disease, starting with laser, injection of steroids or anti-VEGF inside the eye, until pars plana vitrectomy in the advanced stages [7]. The objective of this study to estimate the prevalence and identify the correlation between risk factors like age of patients, type of DM, duration, no control of diabetes mellitus patients with progression of DR attending the Eye Department at Tobruk medical in Tobruk-Libya.

## Materials and Methods

A prospective cross-sectional study of diabetic patients registered at Eye department of Tobruk medical center in Tobruk-Libya between (01.06.2023 to 29.02.2024). Data was collected using self-administered questionnaire. Grading of DR was done by slit-lamp examination and Fundoscopy by ophthalmologist. Descriptive analysis included percentage and mean, median, and p-value by using SPSS 25. Hba1c < 7.5% considered as controlled diabetic patients and >7.5% poor controlled diabetes mellitus patients. Diabetic retinopathy grading divided into no proliferative diabetic retinopathy (mild, moderate and sever), proliferative diabetic retinopathy when complications started with new blood vessels in the retina and advanced DRP when complication of PRP occurred as neovascular glaucoma, vitreous hemorrhage and tractional RD. The diagnosis was done with Slit-lamp examination and lens Volk 78 D. Detailed examination was performed by experienced ophthalmologist. Visual impairment classification considered as WHO visual loss classification, were good or normal vision considered >0.8, mild visual impairment between (0.4-0.8), moderate visual impairment between (0.1-0.3), sever visual impairment between (>HM-0.05), subtotal blindness (HM or PL) and completely blindness no PL.

## Result

In this study; there were 170 eyes of diabetic patients, ages ranged between 30 and 90 years, with a mean of 58 the majority (97.6%) were Libyan nationality living in Tobruk. There were 86 females and 84 males.

The prevalence of diabetic retinopathy was 76.8% of the study cases; mild non- PR was in 46 case (27%) of all cases, whereas moderate non-proliferative retinopathy type was 13% of the cases and sever non-proliferative diabetic retinopathy 5%. Whereas proliferative type was considered in about (33%) of all studying cases. There were 28 out of 56 (50%) of the proliferative diabetic retinopathy cases, considered as advanced stages of PDR, because these cases complicated with severe complications of PDR as vitreous hemorrhage, neovascular glaucoma and tractional retinal detachment; fifteen cases presented with vitreous hemorrhage, ten cases with retinal detachment and three cases with neovascular glaucoma. The most common diabetic eye complication was diabetic retinopathy (76.8%), followed by other correlated risk factors as cataracts (52.9%), neovascular glaucoma in 3 cases (2%), and uveitis one case. Systemic associated disease like systemic hypertension observed in about (40%) and cardiac disease (13%).

The duration of diabetes mellitus ranged between 5 and 40 years, there were (16%) duration of diabetes less than 10 years, whereas for (44) exceeded 15 years and (40%) ranged between 10 and 15 years. The type II Diabetes Mellitus were (90.6%) which they treated with oral medication and diets, and type I-DM 9.4%. The results considered that cases with duration of diabetes ranging between 11 and 15 years were at almost five-folded risk of developing DR compared to those with duration less than 10years, were cases with duration of diabetes more than 15 years two-folded risk of developing DR than cases with duration less than 15 years (Figure 1). In proliferative diabetic retinopathy (PR) most of the cases duration of diabetes more than 15 Years, five-folded than the cases with duration of diabetes less than 15 Years. Most of advanced complicated diabetic retinopathy cases had diabetes more than fifteen years, only 7 cases with duration of diabetes between 10-15 years, and no advanced disease in the cases with duration less than 10 years.

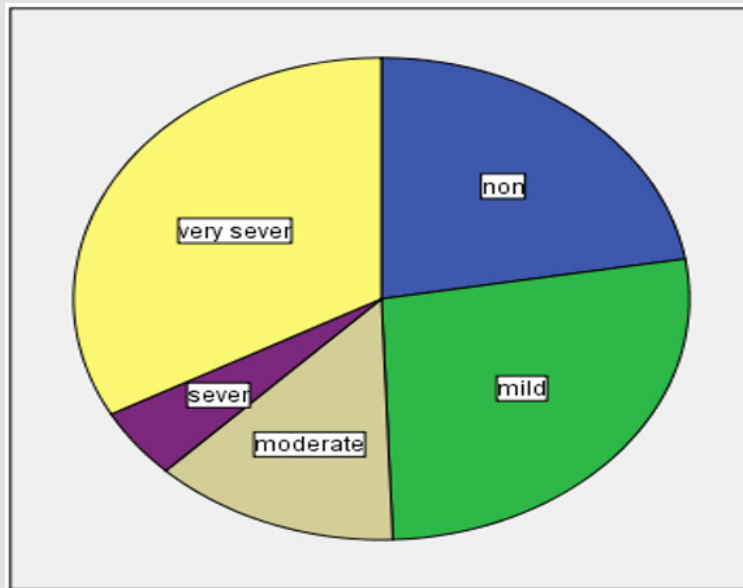


Figure 1: Show the stages of diabetic retinopathy.

There were 142 case (83.5%) with poor control of diabetes mellitus, where HbA1c >7.5% throughout the diabetes and only 28 of the cases be with controlled DM and HbA1c <7.5% throughout the disease. Two cases out of eight of type I (IDDM) be had controlled diabetes, where HbA1c not exceeded 7.5%. Our study considered that cases with poor controlled blood sugar and HbA1c >9 throughout the disease were at almost five-folded risk of developing proliferative diabetic retinopathy compared to those with moderate controlled diabetes cases were HbA1c between (7.5 -9), and patient with poor control of diabetes HbA1c >9 were 25-folded risk of developing PR than cases with good control HbA1c <7.5. The majority of not controlled cases were HbA1c >7.5 throughout the disease, had some degree of diabetic retinopathy. The majority of advanced diabetic retinopathy cases were correlated with non-controlled diabetes mellitus HbA1c > 9%, only four cases with moderate control HbA1c between (7.5-9%). Were no advanced complication recorded in good controlled cases.

Deterioration of vision as indicator for function outcome of the eye recorded in majority of the cases. There were 64 tested eye recorded as mild visual impairment, were visual acuity > 0.3 on Snellen chart. Whereas moderate visual impairments considered in 62 eyes (visual acuity between 0.1-03), severe visual impairment in 18 eyes, visual acuity between (0.05 - > HM), legal or subtotal blindness (vision HM or PL) resulted in 20 eyes, and total blindness (no PL) in 6 eyes of the study. Deterioration of vision is statistically significant related to poor stage of severe diabetic retinopathy. (P value 0.01) and significantly related to poor follow-up cases (P value 0.000). Deterioration of vision is related to severity of the disease, look to Figure 2

Majority of advanced cases presented with severe visual impairment. Look to the Figure 2. Patients with uncontrolled diabetes were at a significantly higher risk of developing of advanced DR compared to those whose disease was good controlled and good follow up. (P < 0.001) (Figures 2-4) (Tables 1 & 2).

Table 1: Stages of diabetic retinopathy in compression to degree of diabetes control by patient’s diet history and HBA1c control and blood sugar level.

Degree of control of DM	Non DRP	Mild non PRP	Mod non PRP	Sever non PRP	PDRP
good controlled*	6	5	0	1	1
mod controlled*	8	11	5	1	4
non controlled*	4	7	6	2	23

Table 2: Test Statistics<sup>a</sup>.

Test Statistics <sup>a</sup>		
	vision - severity	vision - follow-up
Z	-3.317 <sup>b</sup>	-3.925 <sup>b</sup>
Asymp. Sig. (2-tailed)	0.001	000

Note:

- a. Wilcoxon Signed Ranks Test
- b. Based on negative ranks.

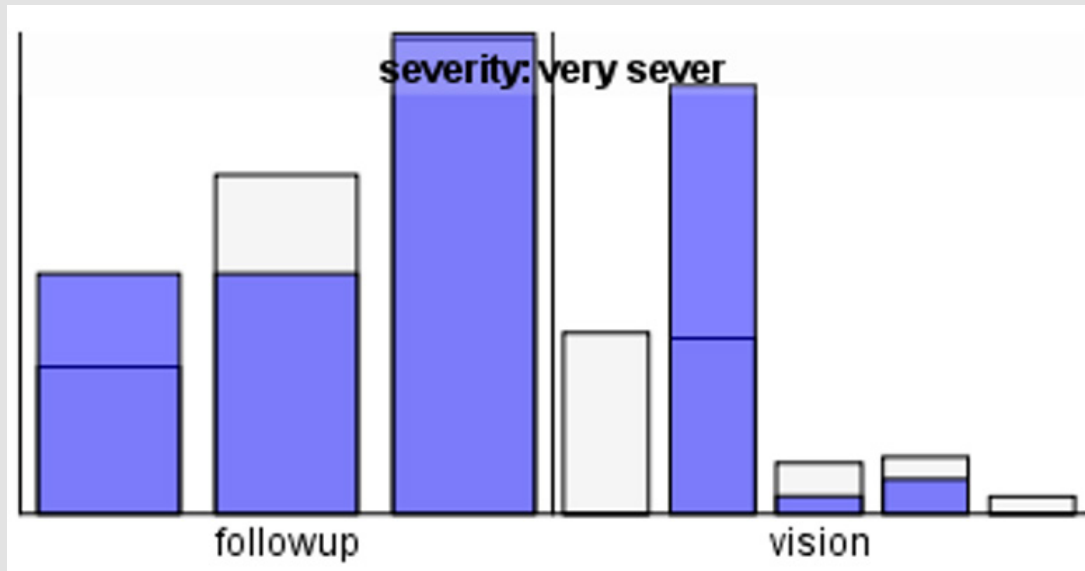


Figure 2.

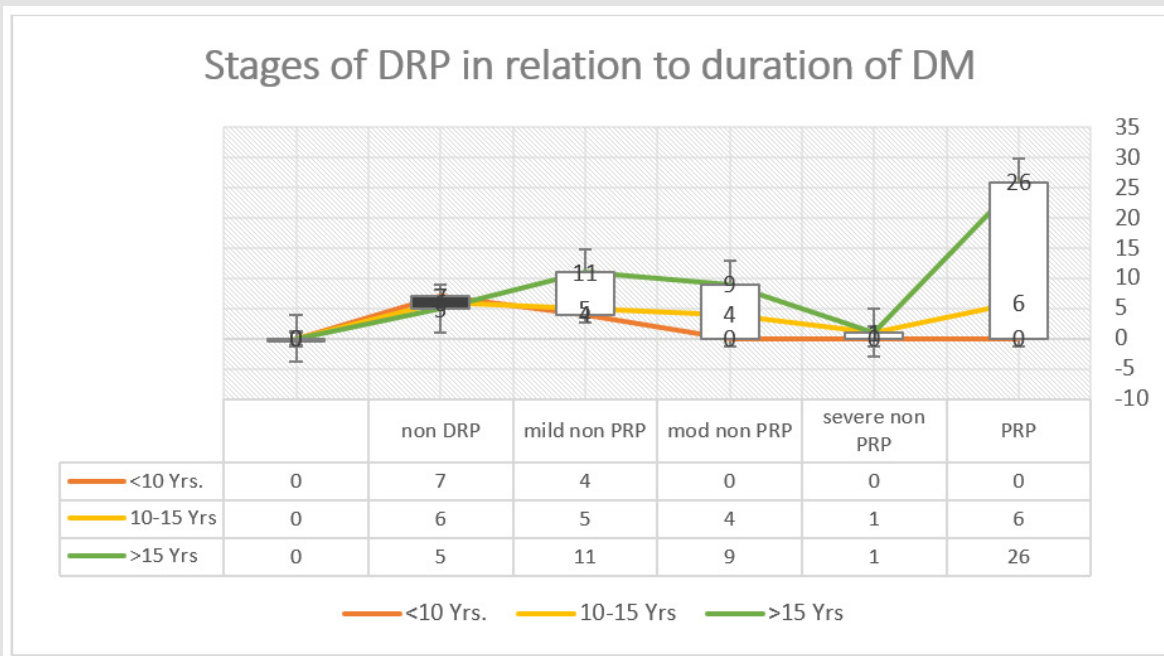


Figure 3: Show progression of DRP in relation to duration of diabetes Miletus.

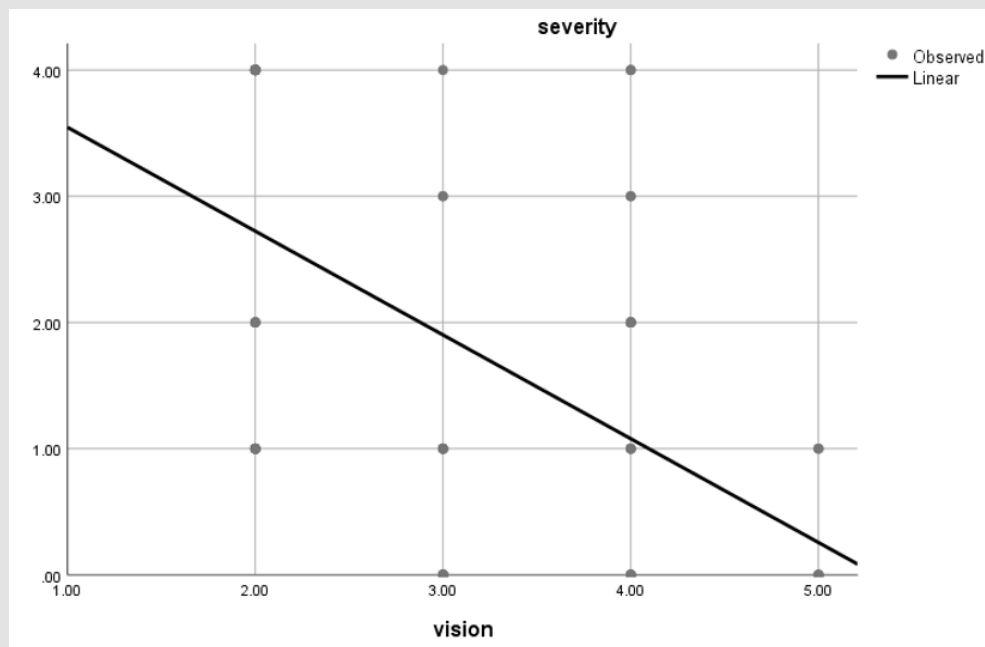


Figure 4: Show the Deterioration of vision with severity of the disease.

## Discussion

Diabetic retinopathy is one of the diabetes mellitus complications which can lead to loss of vision, if not early discovered and properly controlled. For this, we should know DR problem and identifying its associated risk factors, and routinely fundus examination, to detected the RP in early stage, which essential for the achievement of better management to improve the outcome [8]. Our study's overall DR prevalence was 77.6%, which is almost higher to the projected global prevalence of 34.6% among people with diabetes that has been documented, but because most of cases come to our department symptomatic and come to get consultation, which can explain our higher prevalence [9]. In general DR formation in diabetic patient was significantly associated with male patients, older age patients, long duration of disease, uncontrolled HbA1c, adherence to medications and unhealthy diet, irregular diabetes follow-up, irregular fundus examination, patients with history of HTN, dyslipidemia, chronic kidney disease, patients with diabetic complications (cataract, glaucoma, diabetic foot ulcer, renal insufficiency, myocardial infarction [MI], and heart failure), and patients with higher BMI and lower GFR.

Patients' nationality, marital status, place of residence, and family history of diabetes, were not significantly associated with the development of DR [10]. The most frequent risk factors for the detection of DR are type of the diabetes, disease duration, a poor glycemic control (high HbA1c levels), and the presence of other systemic diseases like hypertension was associated with an increased probability of developing DR [11]. Other risk factors for developing DR include obesity,

hyperlipidemia and less exercise. Smoking and obesity did not seem to be important risk factors in this study, was considered with some other studies [12]. however, a report from [13] found that smoking was associated with a higher risk of developing diabetes mellitus. The fact there were fewer people who smoked in the group we studied might be responsible for the above finding [14]. As expected, the uncontrolled patients who did not take regular daily medications and those with as well as those patients they not on regular ophthalmological follow up were at a higher significant risk of developing DR [15].

In the current study, diabetic patients with a long duration of diabetes (10 and 15 years) were at the highest risk for developing DR. The same has been documented in other studies [16]. Concerning the distribution and grading of the retinopathy, the result we obtained from our study are consistent with many of other studies, but in our finding the frequency of proliferative retinopathy is higher in our study than the other studies [17] in current study revealed proliferative diabetic retinopathy prevalence that was higher to the (KSA) study and also higher than that reported from the Ethiopia [18]. One of the complications of diabetes that can lead to blindness is diabetic retinopathy. The first 10 years following a diabetes diagnosis have been designated by a significant decline in visual acuity [19].

Our study's findings support the majority of previous studies in showing that retinopathy worsens with a prolonged period of diabetes. Individuals who have just received a clinical type 2 diabetes diagnosis should be informed that even though age-related vision

loss is inevitable, additional diabetes-related vision loss can be largely avoided with careful ophthalmological monitoring and surgical intervention. Diabetes control, which includes routine doctor visits, a nutritious diet, exercise, and early management with retinal laser photocoagulation and anti-VEGF therapy, is one strategy to lessen vision loss from diabetic retinopathy. In addition, patients with type 1 DM were at higher risk of developing DR (87.5%). The same has been documented in Saudi Arabia, [20] and in Ethiopia. The mechanism of the association between DR and insulin use is still unclear.

## Conclusion

Despite the improvements of health care services, DR still a leading cause of reduce daily life activity and emotional distress due to visual acuity impairment. DR is a serious problem, 40 years patients and older with diabetes have sight-threatening DR. Early detection and treatment of DR can save the vision. For that we need plan DR services to avoid complications of DR as vision loss and to health strategy to improve management of diabetes to decrease risk of DR.

## References

- Ahmed RA, Khalil SN, Al-Qahtani MA (2016) Diabetic retinopathy and the associated risk factors in diabetes type 2 patients in Abha, Saudi Arabia. *J Family Community Med* 23(1): 18-24.
- L P Aiello, T W Gardner, G L King, G Blankenship, J D Cavallerano, et al. (1998) Diabetic retinopathy. *Diabetes Care* 21: 143-156.
- Alali NM, Albazei A, Alotaibi HM, Almohammadi AM, Alsirhani EK, et al. (2022) Diabetic Retinopathy and Eye Screening: Diabetic Patients Standpoint, Their Practice, and Barriers; A Cross-Sectional Study. *J Clin Med* 11: 6351.
- Alemu Mersha G, Alimaw YA, Woredokal AT (2022) Prevalence of diabetic retinopathy among diabetic patients in Northwest Ethiopia-A cross sectional hospital based study. *PLoS ONE* 17(1): e0262664.
- Alharbi AMD, Alhazmi AMS (2020) Prevalence, Risk Factors, and Patient Awareness of Diabetic Retinopathy in Saudi Arabia: A Review of the Literature. *Cureus* 12(12): e11991.
- Mohamed Ashraf, Konstantina Sampani, Abdulrahman Rageh, Paolo S Silva, Lloyd Paul Aiello, et al. (2020) Interaction Between the Distribution of Diabetic Retinopathy Lesions and the Association of Optical Coherence Tomography Angiography Scans With Diabetic Retinopathy Severity. *JAMA Ophthalmol* 138(12): 1291-1297.
- Donald S Fong, Lloyd P Aiello, Frederick L Ferris, Ronald Klein (2004) Diabetic Retinopathy Volume, American diabetic association 7(10).
- Flaxel CJ, Adelman RA, Bailey ST, Fawzi A, Lim JL, et al. (2020) Diabetic Retinopathy Preferred Practice Pattern®. *Ophthalmology* 127(1): P66-P145.
- Hafeez Mohammed, Achar Prashanthkumar, Neeralagi Meghana, Naik Gajaraj T (2022) Correlation between Diabetic Retinopathy and Diabetic Peripheral Neuropathy in Patients with Type II Diabetes Mellitus *Journal of Pharmacy and Bioallied Sciences* 14(Suppl 1): p S658-S661.
- Mohammed Hassan Hussien Hassan, Khaled Mohamed Selim, Ahmad El-sayed Hodeeb, Hanan Mohyi El din El-Ghoneimy (2023) Evaluation of the Choroid in Patients with Non Proliferative Diabetic Retinopathy by Optical Coherence Tomography Angiography (OCTA). *Al-Azhar International Medical Journal* 4(1): Article 11.
- Mohamed F El-Bab, Nashaat Shawky, Ali Al-Sisi, Mohamed Akhtar (2012) Retinopathy and risk factors in diabetic patients from Al-Madinah Al-Munawarah in the Kingdom of Saudi Arabia. *Clinical Ophthalmology* 6: 269-276.
- Xiaoli Li, Jie Xie, Liang Zhang, Ying Cui, Guanrong Zhang, et al. (2020) Differential distribution of manifest lesions in diabetic retinopathy by fundus fluorescein angiography and fundus photography. *BMC Ophthalmol* 20: 471.
- Moudgil T, Bains BK, Bandhu S, Kanda N (2021) Preferred practice pattern of physicians regarding diabetic retinopathy in diabetes mellitus patients. *Indian J Ophthalmol* 69(11): 3139-3143.
- Mounirou BAM, Adam ND, Yakoura AKH, Aminou MSM, Liu YT, et al. (2022) Diabetic Retinopathy: An Overview of Treatments. *Indian J Endocrinol Metab* 26(2): 111-118.
- Biniyam Sahiledengle, Tesfaye Assefa, Wogene Negash, Anwar Tahir, Tadele Regasa, et al. (2022) Prevalence and Factors Associated with Diabetic Retinopathy among Adult Diabetes Patients in Southeast Ethiopia: A Hospital-Based Cross-Sectional Study. *Clin Ophthalmol* 16: 3527-3545.
- Biniyam Sahiledengle, Tesfaye Assefa, Wogene Negash, Anwar Tahir, Tadele Regasa, et al. (2022) Prevalence and Factors Associated with Diabetic Retinopathy among Adult Diabetes Patients in Southeast Ethiopia: A Hospital-Based Cross-Sectional Study. *Clin Ophthalmol* 16: 3527-3545.
- Salem A Alghamdi, Ayla M Tourkmani, Turki J Alharbi, Abdulaziz Bin Rshee, Wedad H Almadani (2021) Prevalence of retinopathy and associated risk factors among high- and low-risk patients with type 2 diabetes mellitus. *Saudi Medical Journal* 42(6): 693-697.
- Yasir ZH, Hassan AD, Rajiv K (2019) Diabetic retinopathy (DR) among 40 years and older Saudi population with diabetes in Riyadh governorate, Saudi Arabia-A population based survey. *Saudi J Ophthalmol* 33(4): 363-368.
- Alharbi S (2020) Challenges and Opportunities for SMEs in the Saudi Arabian Market: A Literature Review. *Journal of Small Business and Enterprise Development* 27: 405-424.
- Alemu MM (2022) Impact of Human Activities on the Ecosystem Services of Nech Sar National Park. In *Human Activity, Biodiversity and Ecosystem Services in Protected Areas*. Springer, pp. 95-119.

ISSN: 2574-1241

DOI: [10.26717/BJSTR.2024.59.009244](https://doi.org/10.26717/BJSTR.2024.59.009244)

Natan katz. Biomed J Sci & Tech Res



This work is licensed under Creative Commons Attribution 4.0 License

Submission Link: <https://biomedres.us/submit-manuscript.php>



#### Assets of Publishing with us

- Global archiving of articles
- Immediate, unrestricted online access
- Rigorous Peer Review Process
- Authors Retain Copyrights
- Unique DOI for all articles

<https://biomedres.us/>