

# Resolution of the Coexisting Sarcoidosis After Treatment of Papillary Thyroid Metastases with Radioactive Iodine. A Case Report

**Hossam El Zeftawy\*, Bilal Rammal and AbdulAziz Khiyami**

*King Faisal Specialist Hospital and Research Center Jeddah, Saudi Arabia*

**\*Corresponding author:** Hossam El Zeftawy, King Faisal Specialist Hospital and Research Center Jeddah, Saudi Arabia

## ARTICLE INFO

**Received:** 📅 February 08, 2024

**Published:** 📅 February 22, 2024

**Citation:** Hossam El Zeftawy, Bilal Rammal and AbdulAziz Khiyami. Resolution of the Coexisting Sarcoidosis After Treatment of Papillary Thyroid Metastases with Radioactive Iodine. A Case Report. Biomed J Sci & Tech Res 55(2)-2024. BJSTR. MS.ID.008669.

## ABSTRACT

**Abbreviations:** SA: Coexistence of Sarcoidosis; CECT: Contrast Enhanced Computed Tomography; PTC: Papillary Thyroid Cancer; Tg: Thyroglobulin

## Introduction

The coexistence of Sarcoidosis (SA) with thyroid malignancy has been reported in many cases [1-3]. Sarcoid-like reaction has also been seen either within the vicinity of the tumor itself or within the regional lymph nodes draining its primary tumor [4]. Abnormal immune response has been suggested for the SA and/or its reactions when it coexists with thyroid diseases [5]. The presence of SA or sarcoid like lymph nodes and soft tissue infiltrations with thyroid cancer makes the diagnosis malignant recurrence and/or metastasis difficult, and a thorough investigation should be done to properly identify the recurrence and/or the metastasis from the coexisting SA or sarcoid-like manifestations. However, the prognosis and clinical course of SA or the sarcoid-like reaction after the treatment of thyroid malignancy has never been described in the literature. We are reporting a case of a 54-year-old lady diagnosed with metastatic papillary thyroid carcinoma with coexisting lymph nodes and pulmonary SA infiltrations. The patient had almost complete resolution of all SA manifestations

after treatment of her metastatic papillary thyroid cancer with high dose radioactive iodine.

## Case Description

A 54-year-old lady with a history of long-standing diabetes mellitus, and hypertension was referred to our hospital with chronic shortness of breath, dry cough and hilar lymphadenopathy. Contrast enhanced computed tomography (CECT) of the chest at presentation is displayed in Figures 1-3. (Figures 1-3) Enumerable bilateral pulmonary nodules (black arrows) with right upper lobe faint interstitial opacities highly suspicious of sarcoid activity and numerous pathologically enlarged mediastinal lymph nodes up to 3.4 cm in size (white arrows). The patient underwent mediastinoscopy and biopsy of mediastinal, neck and paratracheal lymph nodes. Histopathological results showed metastatic papillary thyroid cancer (PTC) at the lymph nodes above the thyroid and granulomatous inflammation with focal necrosis and fibrosis from the mediastinal and paratracheal groups.

Fine needle aspiration of thyroid gland nodule showed papillary thyroid carcinoma. The patient had no history of tuberculosis contact, and all tuberculosis work up came back negative and so tuberculosis was excluded. After total thyroidectomy and lymph nodes dissection, pathologic examination confirmed the presence of multifocal thyroid papillary thyroid carcinoma with multiple lymph node metastases and granulomatous inflammation which showed negative fungal and tuberculosis stains. Post thyroidectomy I123 WB SPECT/CT scan is presented in Figure 4. Non stimulated thyroglobulin (Tg) was not increased. (Figure 4) Focal avid uptake of the tracer at the thyroid gland

with multiple left neck nodes (black arrow) and diffuse bilateral military pulmonary metastases (white arrows). The patient then received 200 mCi radioactive iodine treatment and her I131 post therapy scan again confirmed the results of the pre-therapy I123 dosimetric findings. Follow up CECT seven months later is shown in Figures 5-7 showing resolution of all sarcoid lymph nodes, lung infiltrations as well as the iodine avid peripheral lungs nodules. (Figures 5-7) Almost complete resolution of the pulmonary nodules and mediastinal lesions

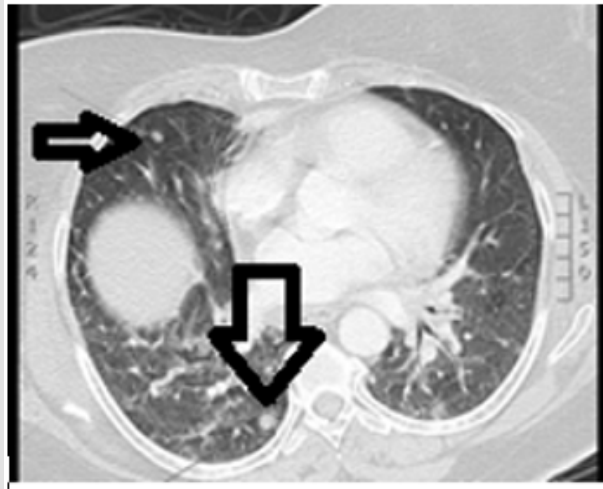


Figure 1:

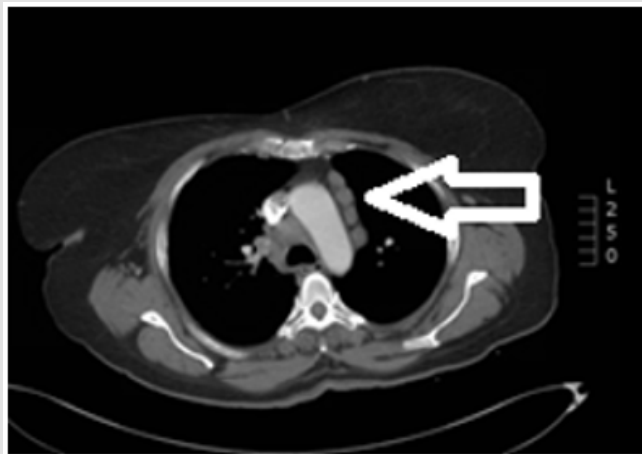


Figure 2:

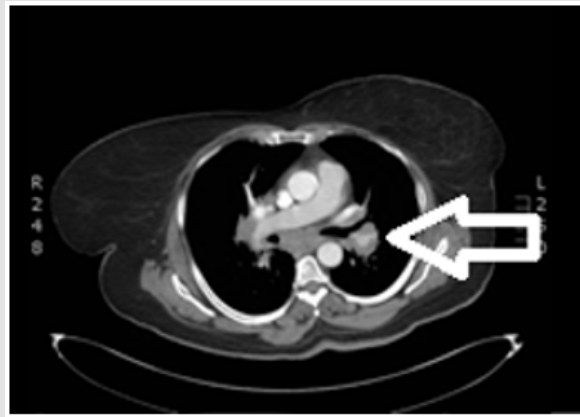


Figure 3.

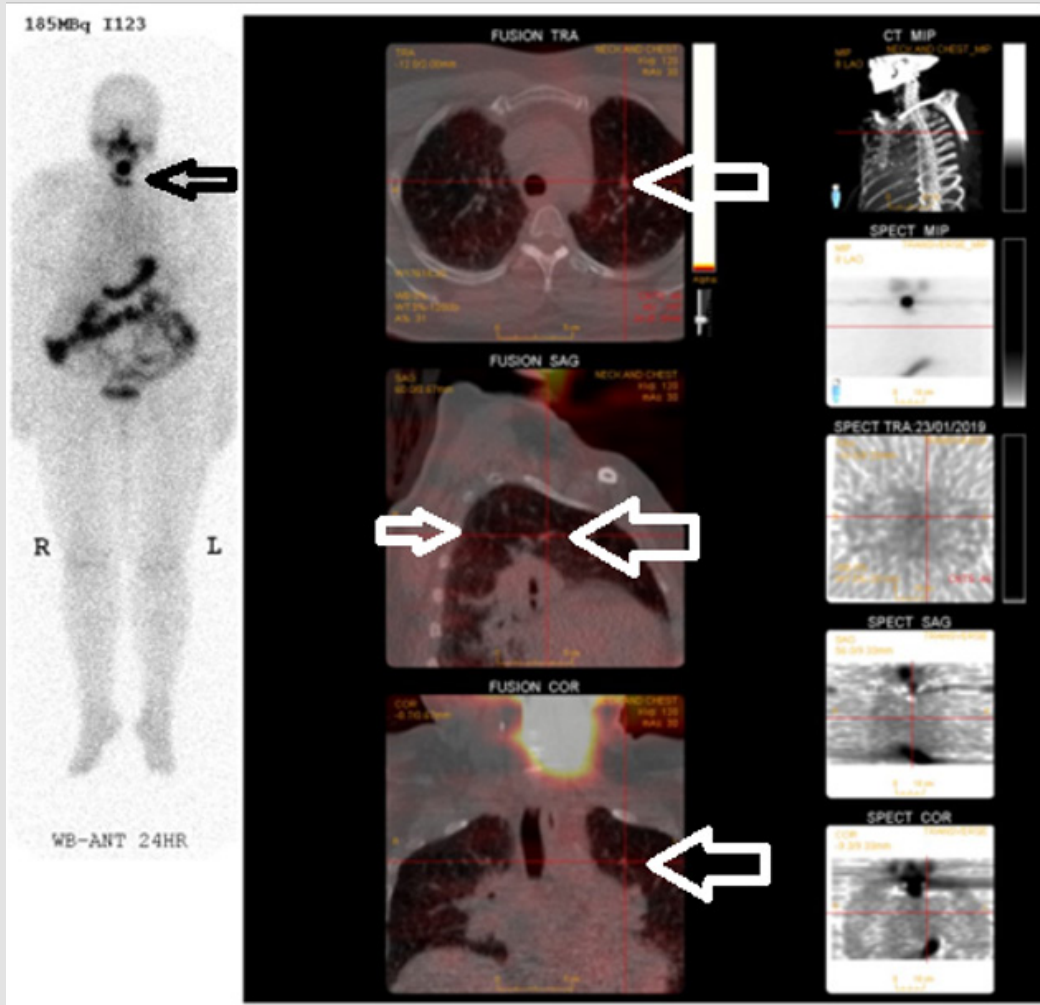


Figure 4.

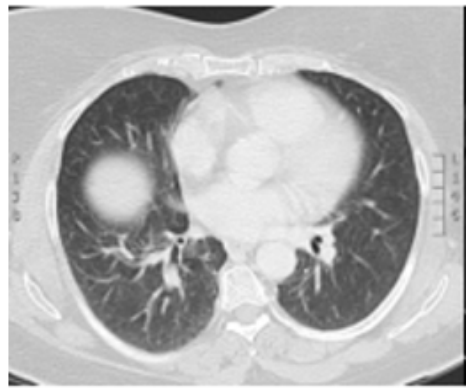


Figure 5.

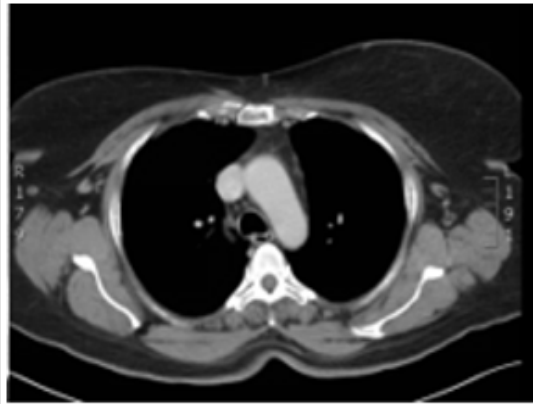


Figure 6.

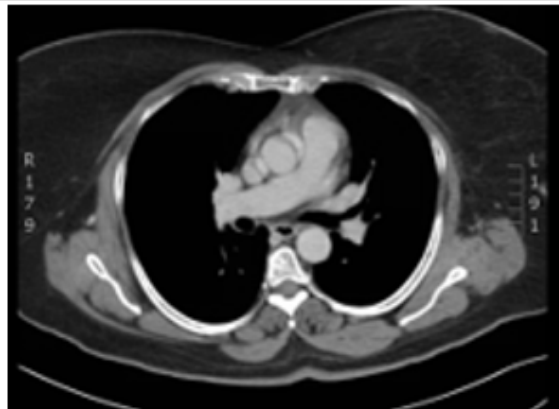


Figure 7.

## Discussion

Sarcoidosis is a well-known granulomatous disorder of unknown etiology [1]. The co-existence of SA and/or sarcoid like reactions with PTC has been reported in several studies [1-3] which makes the diagnosis of malignant recurrence and/or its metastasis difficult without thorough investigations and multiple biopsies [4]. The defected immune system associated with SA and/or sarcoid like reactions can also be a reason for an abnormal serum thyroglobulin (Tg) result, the key marker for follow up of recurrence of differentiated thyroid cancers [5]. In our case, the primary PTC was associated with neck lymph nodes and likely military bilateral pulmonary metastases. SA was diagnosed via pathologic examination of the biopsied mediastinal lymph nodes and transbronchial biopsy of the pulmonary infiltrate as well as the staging CECT criteria. The accumulation of the pre-therapy dosimetry I123 at the neck residual functioning thyroid tissue, neck lymph nodes and bilateral lungs nodules, directed the treatment towards the high dose I131 after surgical resection in spite of the non-diagnostic Tg level. 7 months after the radioactive iodine treatment, the follow up CECT showed almost complete resolution of the neck, mediastinal lymph nodes and the pulmonary manifestations

of SA as well as the bilateral lungs military nodules. This observation again stresses on the causal association between PTC and SA as a paraneoplastic syndrome or sarcoid like reactions to the primary tumor and directs towards the importance of treatment of the primary PTC disease even in the absence of abnormal serum Tg as a marker for recurrence in lieu of the defected immune system.

## References

1. H brincker, E wilbek (1974) The incidence of malignant tumours in patients with respiratory sarcoidosis. Br J Cancer 29: 247.
2. Salih AM, Fatih SM, Kakamad FH (2015) Sarcoidosis mimicking metastatic papillary thyroid cancer. International journal of surgery case reports 16: 71-72.
3. Myint ZW, Chow RD (2015) Sarcoidosis mimicking metastatic thyroid cancer following radioactive iodine therapy. Journal of community hospital internal medicine perspectives 5(1): 26360.
4. Shweta Nag (2010) Sarcoid-Like Reactions. Meenakshi University,India. Chaper 16: 253.
5. Piera Fazzi, Poupak Fallahi, Silvia Martina Ferrari (2017) Sarcoidosis and Thyroid Autoimmunity. Front Endocrinol (Lausanne).

ISSN: 2574-1241

DOI: 10.26717/BJSTR.2024.55.008669

Hossam El Zeftawy. Biomed J Sci & Tech Res



This work is licensed under Creative Commons Attribution 4.0 License

Submission Link: <https://biomedres.us/submit-manuscript.php>



### Assets of Publishing with us

- Global archiving of articles
- Immediate, unrestricted online access
- Rigorous Peer Review Process
- Authors Retain Copyrights
- Unique DOI for all articles

<https://biomedres.us/>