

# Effect of Natural Deuterium Depleted Water on Survival Time and Oxidative Damage to Liver Tissues of <sup>60</sup>Co-γ Rays Irradiated Mice

Meng-yao Ma<sup>1</sup>, Yu Cong<sup>2</sup>, Feng Hu<sup>3\*</sup> and Feng-song Cong<sup>1\*</sup>

<sup>1</sup>College of Life Sciences and Technology, Shanghai Jiaotong University, China

<sup>2</sup>Shanghai Starriver Bilingual School, China

<sup>3</sup>Department of Respiratory and Critical Care Medicine, Tongren Hospital, Shanghai Jiao Tong University School of Medicine, China

**\*Corresponding author:** Feng Hu, College of Life Sciences and Technology, Shanghai Jiaotong University, Shanghai 200240, China

Feng-song Cong, Department of Respiratory and Critical Care Medicine, Tongren Hospital, Shanghai Jiao Tong University School of Medicine. Shanghai 200336, China

## ARTICLE INFO

**Received:** 📅 October 27, 2023

**Published:** 📅 November 08, 2023

**Citation:** Meng-yao Ma, Yu Cong, Feng Hu and Feng-song Cong. Effect of Natural Deuterium Depleted Water on Survival Time and Oxidative Damage to Liver Tissues of <sup>60</sup>Co-γ Rays Irradiated Mice. Biomed J Sci & Tech Res 53(4)-2023. BJSTR. MS.ID.008435.

## ABSTRACT

**Objective:** To study the protection of natural deuterium depleted water against oxidative damage to liver tissues of irradiated mice.

**Method:** 31 KM male mice were randomly divided into three groups: blank control group, ordinary water irradiation group, and DDW irradiation group. Except for the blank control group, the other two groups were given a single dose of 10 Gy <sup>60</sup>Co-γ total body irradiation. After 6 days of irradiation, the survival rate, content of malondialdehyde (MDA) in liver tissues, and effects of superoxide dismutase (SOD) and glutathione peroxidase (GPX) activities were measured in each group of mice, and the liver tissues of the three groups of mice were stained with hematoxylin eosin (HE).

**Results:** Compared with the ordinary water irradiation group, the natural deuterium depleted water significantly increased SOD and GPX activities and improved the irradiation damage (p<0.05). The HE staining results demonstrated that the natural low deuterium water irradiation group reduced the degree of liver cell necrosis and inflammatory infiltration in mice.

**Conclusion:** DDW has a protective effect on oxidative damage to liver tissues caused by ionization irradiation.

**Keywords:** Ionization Irradiation; Natural Deuterium Depleted Water; Liver Tissue; Oxidative Damage

**Abbreviations:** DDW: Deuterium Depleted Water; SOD: Superoxide Dismutase; GPX: Glutathione Peroxidase; HE: Hematoxylin Eosin

## Introduction

Ionizing radiation is currently widely applied in industry, agriculture, and medical fields, which, however, is still one of the types of irradiations that cause serious harm to humans [1]. It can trigger ionization reactions in irradiated materials, produce various free radicals, and cause DNA strand breaks, damage to biological macromol-

ecules, cell apoptosis, and even damage to multiple organ tissues [2]. Accordingly, the study of effective radioprotectant is crucial. In nature the ratio of deuterium to hydrogen (D/H) is about 1:6600; this means that the natural concentration of D is about 150 ppm (0.015 atom%). Water with a deuterium volume fraction lower than 0.0015% is called deuterium depleted water (DDW), which presents biological functions such as antioxidation [3], anti-tumor [4,5], and blood sugar low-

ering [6,7] and radioresistance [8,9]. However, these experiments are all conducted on artificially low deuterium water, and their deuterium concentration is usually lower than 130ppm. Glacier water is the best naturally low deuterium water in the worlds, with deuterium concentrations typically between 131 and 143 ppm. Scientists from many countries have conducted a series of studies on the benefits of drinking glacier water regularly, such as improving human health, reducing diseases, and prolonging lifespan. However, the radioprotective effect of naturally occurring D in the glacier water has never, so far as we are aware, been investigated. This study measured the contents of lipid peroxide products and antioxidant enzyme activities in liver tissues of irradiated mice, and preliminarily explored the protective effect of natural deuterium depleted water (DDW) on irradiation-induced liver tissue damage in mice.

## Instruments and Materials

### Materials and Reagents

Natural deuterium depleted water ( $\delta$ -value -90~-150) is provided by Xinjiang Xuedu Glacier Water Co., Ltd.

BCA protein assay kit (Wuhan Servicebio, G2026-1000T); Malondialdehyde (MDA) assay kit (Wuhan Servicebio, G4300-96T); Total superoxide dismutase (SOD) assay kit (Nanjing Jiancheng, A001-1); Glutathione peroxidase (GPX) assay kit (Nanjing Jiancheng, A005);

### Experimental Animals

31 SPF KM mice, male, weighing 20-22g, purchased from Jiangsu Huachuang Sino Pharmaceutical Technology Co., Ltd. (license No.: scxk (S) 2020 0009).

## Method

### Experimental Grouping

After 2 days of adaptive feeding, 31 KM mice were randomly divided into 3 groups. There were 10 mice in the blank control group (control group), 10 mice in the purified water + irradiation group (ordinary water irradiation group), and 11 mice in the natural deuterium depleted water (DDW) + irradiation group (DDW irradiation group). The mice in the ordinary water irradiation group freely drank purified water; the DDW irradiation group mice freely drank natural deuterium depleted water.

### Construction of an Ionization Irradiation Damage Model

After 20 days of group feeding, except for the blank control group, the other two groups were given a single dose of 10 Gy  $^{60}\text{Co}$   $\gamma$  total body irradiation. After 6 days of irradiation, the mice were euthanized. The survival of mice after irradiation was recorded, the liver tissues dissected, and all biochemical indicators measured.

### Determination of MDA Content in Liver Tissues of Mice

Liver tissue extraction: PBS=1g: 10 mL of homogenate was lysed, the resulting tissue homogenate centrifuged at 4°C at 10,000 g for 10-15 minutes, and the supernatant taken for subsequent MDA detection. The BCA protein assay kit was used to detect the protein concentration of liver tissue homogenate. MDA standard/PBS/liver tissue homogenate/MDA detection working solution were added to a 1.5 mL EP tube according to the instructions, incubated at 95°C for 40 minutes, immediately ice bathed for 5 minutes, and centrifuged at 10,000 g for 10 minutes; 200  $\mu\text{L}$  supernatant was placed in a transparent 96-well plate and the absorbance at 532 nm was detected using an enzyme-linked immunosorbent assay. The MDA content in each group of samples was calculated according to the instructions.

### Determination of SOD Content in Liver Tissues of Mice

The preparation of liver tissue homogenate and protein concentration detection were made by reference to 2.3; according to the instructions, the corresponding reagents were prepared; the liver tissue homogenate and various reagents were added to a 1.5 mL EP tube and incubated at 37°C in a constant-temperature incubator for 40 minutes; the chromogenic agent was added and mixed completely; they were stood at room temperature for 10 minutes, and adjusted to zero with distilled water at 550 nm for colorimetry. The SOD activity in each group of samples was calculated according to the instructions.

### Determination of GPX Content in Liver Tissues of Mice

The preparation of liver tissue homogenate and protein concentration detection were made by reference to 2.3; according to the instructions, the corresponding reagents were prepared; the liver tissue homogenate and various reagents were added to a 1.5 mL EP tube; the reagents were added according to the instructions for enzymatic and colorimetric reactions; the chromogenic agent was added and mixed completely; they were stood at room temperature for 15 minutes, and adjusted to zero with distilled water at 412 nm for colorimetry. The GPX activity in each group of samples was calculated according to the instructions.

### HE Staining Detection of Pathological Changes in Liver Tissue Slices of Mice

After the mice were euthanized, the liver tissue was fixed with paraformaldehyde, and paraffin sections were made; after HE staining and sealing, images were captured.

### Statistical Processing

SPSS 9.5 experimental data was used for analysis, one-way ANOVA was employed for inter-group comparison, and Graphpad 7.0 software was utilized for plotting.  $P < 0.05$  indicates a statistically significant difference.

## Results and Analysis

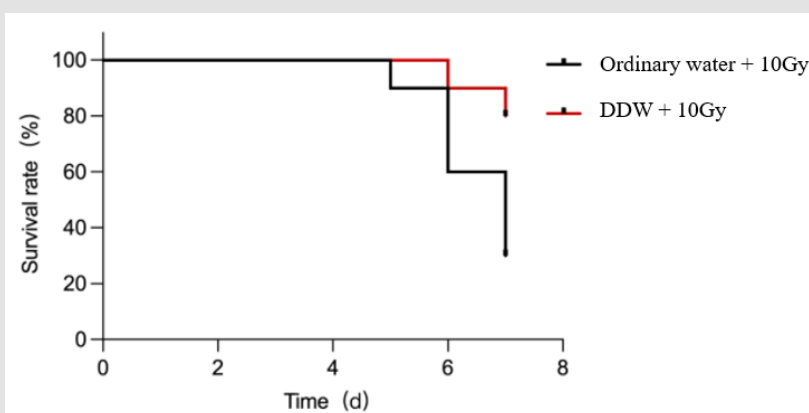
### The Effect of DDW on the Survival Rate of Irradiated Mice

The effect of DDW on the 7-day survival rate of mice is shown in Table 1 and Figure 1. Death occurred to the ordinary water irradiation

group first 4 days after irradiation, and the survival rate of the mice remained only 30% until 6 days after irradiation. The survival rate of mice in the DDW irradiation group significantly grew, with mouse death occurring only 5 days after irradiation, and the survival rate at 6 days after irradiation was 80%. It demonstrates that DDW has a protective effect on 10 Gy<sup>60</sup>Co  $\gamma$  irradiation damage.

**Table 1:** Survival of irradiated mice after 7 days (n=10).

	Time After Irradiation/d							Number of Deaths/Animal	Death rate/%	Survival Rate In 7 Days/Animal	Survival Rate In 7 Days/%
	0	+1	+2	+3	+4	+5	+6				
Ordinary water + 10 Gy	0	0	0	0	1	3	3	7	70	3	30
DDW + 10 Gy	0	0	0	0	0	1	1	2	20	8	80

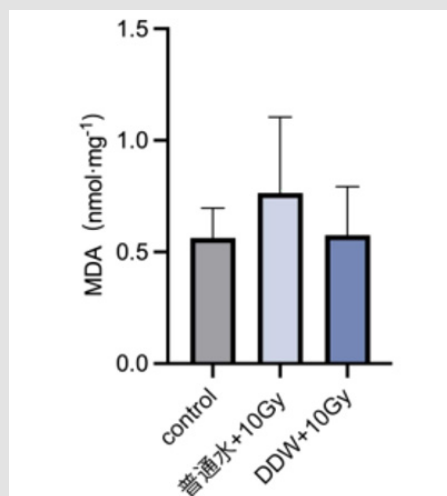


**Figure 1:** The effect of DDW on 7-day survival rate of 10 Gy <sup>60</sup>Co  $\gamma$ -rays irradiated mice.

### The Effect of DDW on MDA Content in Liver Tissues of Irradiated Mice

Compared with the control group, the MDA levels in the liver tissues of mice in the ordinary water irradiation group rose, while those

in the DDW irradiation group declined compared to the ordinary water irradiation group. Although the differences between the groups were not significant, it is shown that certain damage was caused to the mice in the irradiation group, as shown in Figure 2.



**Figure 2:** The effect of DDW on MDA content in liver tissues of irradiated mice.

### The Effect of DDW on SOD Activity in Liver Tissues of Irradiated Mice

Compared with the control group, the SOD activity of liver tissues in mice of the ordinary water irradiation group fell; although the dif-

ference between the control group and the ordinary water irradiation group was not significant, certain damage was caused to the mice of the irradiation group. Compared with the ordinary water irradiation group, the SOD activity in the DDW irradiation group went up with statistical significance ( $p < 0.05$ ), as shown in Figure 3.

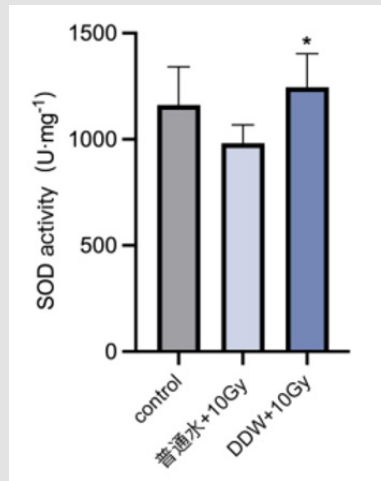


Figure 3: The effect of DDW on SOD activity in liver tissues of irradiated mice.

### The Effect of DDW on GPX Activity in Liver Tissues of Irradiated Mice

Compared with the control group, the GPX activity in the liver

tissues of mice in the ordinary water irradiation group decreased. Compared with the ordinary water irradiation group, the GPX activity in the DDW irradiation group went up with statistical significance ( $p < 0.05$ ), as shown in Figures 2 & 4.

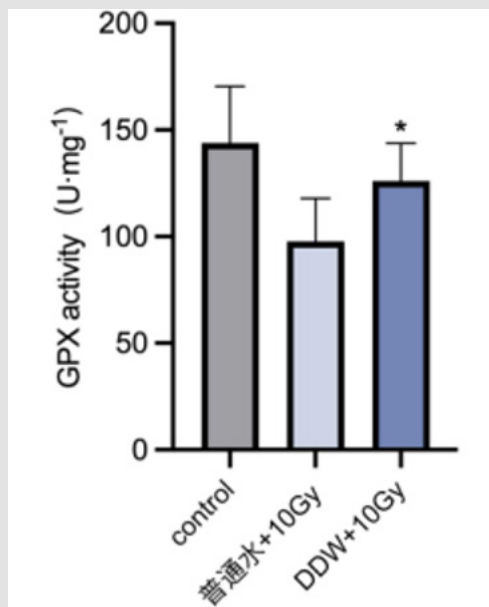


Figure 4: The effect of DDW on GPX activity in liver tissues of irradiated mice.

## The Effect of DDW on HE Staining Pathology in Liver Tissues of Irradiated Mice

The HE staining results are shown in Figure 5. The liver tissue structure of the control group was clear, with regular arrangement of liver cells, clear contour of liver lobules, no deformation or necrosis of liver cells, and no inflammatory reactions; the liver tissues of the or-

dinary water irradiation group showed more liver cell degeneration (black arrow), and the cytoplasm was loose and light stained; multiple liver cell lysis and necrosis were visible, accompanied by local inflammatory cell infiltration (red arrow); although the liver cell degeneration (black arrow) was observed in the DDW irradiation group, the liver cell necrosis and inflammatory infiltration were reduced to varying degrees compared to the ordinary water irradiation group.

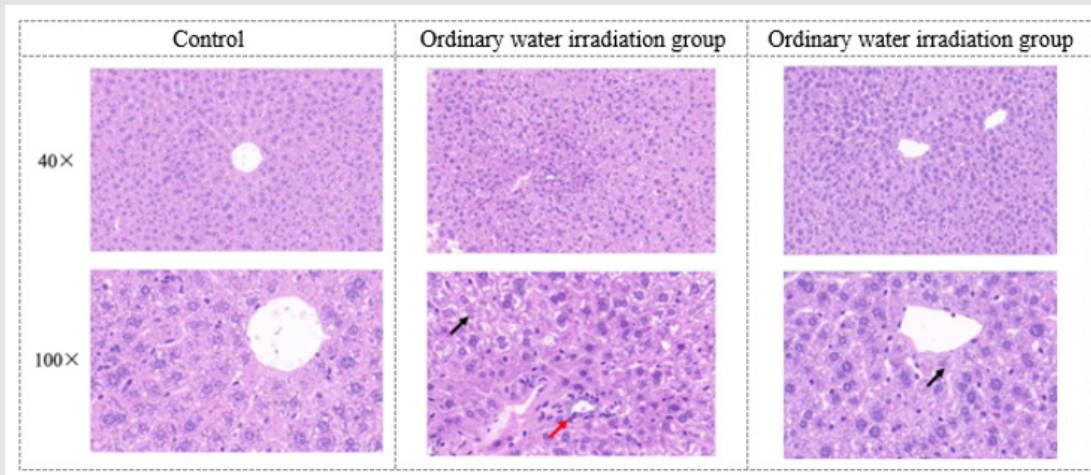


Figure 5: HE is staining observation of liver tissue pathology results in each group of mice (40×, 100×).

## Conclusion

Ionization irradiation is widely used in fields such as medicine, industry, and agriculture, while radiation medicine and ionization accidents also cause damage to normal organs and tissues of the human body [1]. Although the existing radioprotectants and drugs produce significant effects, there are adverse reactions such as headache, nausea, and vomiting [5]; thus, it is urgent to develop safe, reliable, effective, and side-effect-free radioprotectants. The previous reports have indicated that DDW can significantly reduce tumor growth and has a series of biological effects such as antioxidation and hypoglycemic effects [4]. Nonetheless, it is unclear whether DDW has a protective effect on oxidative damage to liver tissues of mice after ionization irradiation. In consequence, based on the existing studies, this experiment further investigated the anti-irradiation effects of DDW, in order to explore the potential value of DDW in clinical applications more deeply. Ninety percent of DNA damage due to ionization irradiation is the result of free radicals, and thus, clearing free radicals in the body is a quick way to protect the body and effectively reduce the irradiation damage. SOD and GPX, as key enzymes in the antioxidation system, play important antioxidation roles in the body. MDA is a metabolite of lipid peroxides, which can disrupt normal cellular function and lead to abnormal cellular metabolism. Consequently, improving the activities of SOD and GPX and reducing the content of MDA are effective methods to reduce the generation of free radicals by irradiation.

The results of this study manifest that 10 Gy  $^{60}\text{Co}\gamma$ -rays irradiated KM mice showed the lowered activities of SOD and GPX in the liver tissues of mice, indicating a weakened antioxidant capacity, while DDW can upregulate the activities of SOD and GPX in the liver tissues of the mice, thereby improving their antioxidant capacity. Meanwhile, some studies have suggested that ionization irradiation can cause DNA strand breakage and produce various free radicals, which may further lead to pathological changes in the body's tissues, such as inflammatory infiltration, proliferation and congestion [9]. To further investigate the protective effect of DDW on liver tissues of ionization irradiated mice, HE staining was performed on the liver tissues of control group, ordinary water irradiation group, and DDW irradiation group, with the results showing that the liver cell necrosis and inflammatory infiltration in mice of the DDW irradiation group were lowered. In summary, the results of this study indicate that natural deuterium depleted water has a protective effect on the oxidative damage of 10 Gy  $^{60}\text{Co}\gamma$ -rays irradiated mice, providing the experimental basis for the development of DDW as a radioprotectant and improvement of the body's resistance to irradiation damage in the future.

## References

1. Driscoll CB, Schuelke MR, Kottke T, Jill M Thompson, Phonphimon Wongthida, et al. (2020) APOBEC3B-mediated corruption of the tumor cell immunopeptidome induces heteroclitic neoepitopes for cancer immunotherapy. *Nature Communications* 11(1): 790.

- Ikeda K, Mahyuddin MH, Shiota Y, Aleksandar Staykov, Takahiro Matsmoto, et al. (2020) Computational study on the light-induced oxidation of iridium-aqua complex to iridiumoxo complex over WO<sub>3</sub>(001) surface. *InorgChem* 59(1): 415-422.
- Zhang XP, Gaetani M, Chernobrovkin A, Roman A Zubarev (2019) Anticancer effect of deuterium depleted water-redox disbalance leads to oxidative stress. *Mol Cell Proteomics* 18(12): 2373-2387.
- Gyöngyi Z, Budán F, Szabó I, István Ember, István Kiss, et al. (2013) Deuterium Depleted Water Effects on Survival of Lung Cancer Patients and Expression of Kras, Bcl2, and Myc Genes in Mouse Lung. *Nutr Cancer* 65(2): 240-246.
- Somlyai G (2012) Use of deuterium depleted water for the treatment of insulin resistance. CA Patent CA2805313A1 12.
- Molnár M, Horváth K, Dankó T, Ildikó Somlyai, Beáta Zs Kovács, et al. (2021) Deuterium depleted water stimulates GLUT4 translocation in the presence of insulin, which leads to decreased blood glucose concentration. *Molecular and Cellular Biochemistry* 476(12): 4507-4516.
- Bild W, Năstăsă V, Hăulică I, C Lupuşoru, G Titeşcu, et al. (1999) Research concerning the radioprotective and immuno stimulating effects of deuterium-depleted water. *Romanian Journal of Physiology* 36(3-4): 205-218.
- Corneanu GC, Corneanu M, Crăciun C, Marin Zagnat, Ioan Stefanescu, et al. (2010) The radioprotective effect of deuterium depleted water and polyphenols. *Environmental Engineering and Management Journal* 9(11): 1509-1514.
- Khan S, Kumar A, Adhikari JS, MA Rizvi, NK Chaudhury (2015) Protective effect of sesamol against 60Co  $\gamma$ -ray-induced hematopoietic and gastrointestinal injury in C57BL/6 male mice. *Free Radic Res* 49(11): 1344-1361.

ISSN: 2574-1241

DOI: 10.26717/BJSTR.2023.53.008435

Feng Hu and Feng-song Cong. Biomed J Sci & Tech Res



This work is licensed under Creative Commons Attribution 4.0 License

Submission Link: <https://biomedres.us/submit-manuscript.php>



#### Assets of Publishing with us

- Global archiving of articles
- Immediate, unrestricted online access
- Rigorous Peer Review Process
- Authors Retain Copyrights
- Unique DOI for all articles

<https://biomedres.us/>