

Thyroid Storm Secondary to Follicular Neoplasm of the Thyroid

T Patrick Jensen^{1*}, Hannah Smith² and Manyata Bhattarai³

¹Medical Director of Consult & Liaison Service and Senior Behavioral Unit, Covenant Health, USA

²MA, OMS-III, USA

³LMU-DCOM Harrogate, USA

***Corresponding author:** T Patrick Jensen, Medical Director of Consult & Liaison Service and Senior Behavioral Unit, Covenant Health, USA

ARTICLE INFO

Received: 📅 September 26, 2023

Published: 📅 October 26, 2023

Citation: T Patrick Jensen, Hannah Smith and Manyata Bhattarai, Y Abouel-seoud, AM AbdEl latief and AA Haridy. Thyroid Storm Secondary to Follicular Neoplasm of the Thyroid. Biomed J Sci & Tech Res 53(3)-2023. BJSTR. MS.ID.008410.

ABSTRACT

Abbreviations: RVR: Rapid Ventricular Response; PCP: Primary Care Provider; TSH: Thyroid Stimulating Hormone; SEER: Surveillance Epidemiology and End Results; PTC: Papillary Thyroid Carcinoma; ATC: Anaplastic Thyroid Carcinoma

Case Report

The patient is an 80-year-old White man with a past medical history of atrial fibrillation, left ventricular hypertrophy, and hyperlipidemia who presented to the hospital at the request of his primary care provider (PCP) for discovery of atrial fibrillation with rapid ventricular response (RVR). In the patient's PCP office, he reported a three day history of palpitations, eye swelling, and presyncope. An ECG in the PCP's office revealed atrial fibrillation with a heart rate of 135 beats per minute. He was admitted to the hospital under Cardiology's service and started on 180 mg of IV Diltiazem with plan for TEE, but spontaneously converted to normal sinus rhythm while awaiting this procedure. He also started on metoprolol tartrate 50 mg PO twice daily. The patient was anticoagulated on rivaroxaban 20 mg PO QPM. Initial physical exam demonstrated the following:

Physical Examination Upon Admission

- a. **Vital Signs:** T - 36.5 C, HR - 156, RR - 20, BP - 113/73, SpO2 - 97%.
- b. **Constitutional:** Alert and oriented, no acute distress
- c. **HEENT:** Head is normocephalic, vision grossly intact
- d. **Resp:** Clear to auscultation bilaterally no diminished breath sounds and chest non tender
- e. **CV:** S1-S2 irregular irregular no gallops murmurs or rubs PMI is non displaced
- f. **GI:** Soft, non tender; non distended, normoactive bowel sounds
- g. **MSK/ext:** No pedal edema no cyanosis
- h. **Skin:** Normal temp, no rash, intact
- i. **Neuro:** No focal neuro deficits appreciated, moving all extremities
- j. **Psych:** Mood and affect appropriate, cooperative

Initial labs were drawn upon admission and showed a markedly abnormal TSH at 0.006 mICU/mL. Subsequent total T3 was elevated at >6.5 ng/mL and free T4 was also elevated at >7.7 ng/dL. A neck ultrasound was then performed and showed bilateral thyroid nodules, the largest measuring at 1.46 cm x 1.57 cm (Figure 1). The recommendation was made for a biopsy of the largest right thyroid nodule per ACR TI-RADS criteria. On day two of the patient's admission, Medicine was consulted for management of his new hyperthyroidism. The patient denied any prior history of thyroid disease. He started on methimazole 10 mg PO twice daily. On day 3 of the patient's admission, the metoprolol tartrate was increased to 75 mg PO every 6 hours after it was found that the patient had converted back to atrial fibrillation

with RVR. On day 4 of the patient's admission, he had converted back to normal sinus rhythm, but developed worsening confusion per family and nursing staff. He was alert but disoriented to person, place, and time. He did not demonstrate any focal neurological deficits. Family reported that the patient has a history of chronic daily alcohol use. A urinalysis and CT head were ordered. The urinalysis showed no abnormalities, including signs of infection or renal pathology. The CT scan of the head showed atrophy and chronic small vessel ischemic change with no acute intracranial findings. The patient continued to be confused into day 5 of his admission, pulling his IV out and tearing off his telemetry stickers. Behavioral Medicine was then consulted for delirium and agitation.

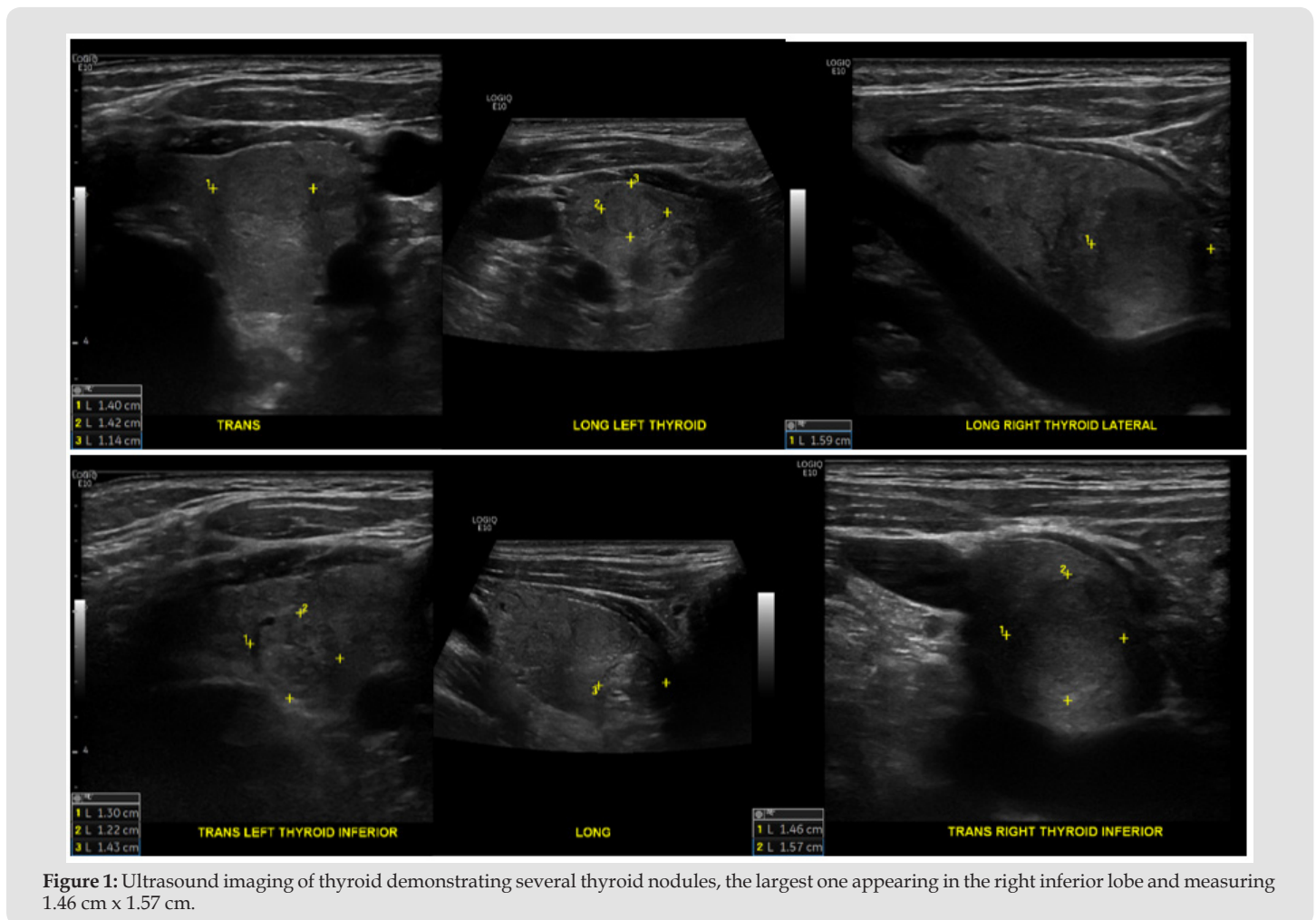


Figure 1: Ultrasound imaging of thyroid demonstrating several thyroid nodules, the largest one appearing in the right inferior lobe and measuring 1.46 cm x 1.57 cm.

The consult liaison psychiatric team reported the following history of present illness:

"This 80-year-old patient with no previous psychiatric history has developed altered mental status in the context of thyroid storm. The patient was a poor historian and was alert, but disoriented in all four domains. He does not have a history of psychiatric illness or of

dementia. The nursing staff had to place soft restraints in the room, and security had to be present, as the patient had been combative. The patient reported that his mood is fine, but his sleep is poor, and his energy is elevated. He also reported poor concentration as well as appetite. All other psychiatric review of systems were unremarkable. The patient did acknowledge being confused.

Substance Use History

The patient drinks 1-2 beers per day. He was a heavy drinker remotely, but does not have a history of withdrawal symptoms or seizures. He does not use any other illicit drugs or tobacco products.

Social History

The patient has a college education, and receives social security income. He has never been arrested and there is no history of physical or sexual abuse.

Mental Status Exam

- a. **Appearance:** Appropriately Dressed And Groomed
- b. **Behavior/Mood Activity:** Restlessness, Agitation
- c. **MSK:** Observed Muscle Strength/Tone Within Normal Limits
- d. **Gait/Station:** Not Observed
- e. **Speech:** Normal
- f. **Mood:** Fair
- g. **Affect:** Constricted
- h. **Thought Process/Associations:** Loose Associations
- i. **Thought content:** Distorted
- j. **Cognition/Attention/Memory/Concentration:** disoriented, Inattentive during the interview and requires redirection
- k. **Insight:** poor
- l. **Judgment:** poor
- m. **Language:** Within Normal Limits
- n. **Fund of Knowledge:** Limited

Vitals

- a. **T:** 36.7 C
- b. **HR:** 116
- c. **RR:** 19
- d. **BP:** 109/66
- e. **SpO2:** 97% on Room Air
- f. **Height:** 172.7 cm
- g. **Wt:** 78.1 kg
- h. **BMI:** 26.5"

The consult liaison psychiatry team recommended the patient start Haldol 5 mg IV every 4 hours as needed for his agitation and

Ativan therapy and folate and thiamine repletion was started through CIWA protocol for possible alcohol withdrawal. A urine drug screen was also ordered as this was not obtained at the time of admission, but was ultimately unremarkable. Plasma metanephrines were ordered as well to rule out possible secretion of adrenergic hormones from the thyroid gland that could be contributing to this patient's hemodynamic instability. They were eventually found to be within normal limits. A paraneoplastic antibody panel was ordered as well which also came back negative. Additionally, on day 5 of the patient's hospital admission, he underwent a successful ultrasound-guided core biopsy of the right thyroid nodule. The pathology report demonstrated concern for follicular neoplasm. The microscopic description was as follows:

"Multiple levels examined. The histologic sections demonstrate round follicles of varying size, some containing colloid and others apparently empty, lined by uniform population of tall cells with abundant, eosinophilic cytoplasm, round nuclei at the apical ends of the cells, occasional, moderate nuclear pleomorphism, normal quality chromatin without grooves, pseudoinclusions, or ground-glass texture, apical snouts, and rare mitotic figures. The undulating heights of the epithelial cells give some follicles a stellate lumen." The patient was found to be in atrial fibrillation again and his metoprolol tartrate dose was increased to 100 mg PO every 8 hours. He continued to be confused and was combative with staff again. He was given Haldol and was started on Seroquel at that time.

On day 6, the patient's methimazole dose was also increased to 20 mg PO three times daily to attempt to control the patient's thyroid hormones that may be contributing to his hemodynamic instability and delirium. The patient continued to be confused and was temporarily placed in restraints with a sitter remaining at bedside. The patient was able to come out of restraints on day 7 of his hospital admission, although he still remained confused. Oncology was consulted and recommended a CT scan of the patient's neck to evaluate for metastases to surrounding lymph nodes. The CT scan of the neck did not show any lymphadenopathy or areas concerning for metastases (Figure 2). A surgical consult was also placed and outpatient endocrinology and ENT follow-up was recommended. Per Psychiatry's recommendation, CIWA protocol was discontinued so as to not exacerbate his delirium with Ativan therapy and as-needed Haldol was continued for his agitation. The surgeon advised that the patient's thyrotoxicosis was likely due to a dysfunction of the entire gland rather than a hyperactive solitary thyroid nodule. The surgeon recommended prioritizing management of his delirium and hemodynamic instability before pursuing thyroidectomy, as the elevated thyroid hormones currently in his system would pose risk for complications during surgery. Additionally, radioactive ablation was not an option in the inpatient setting.

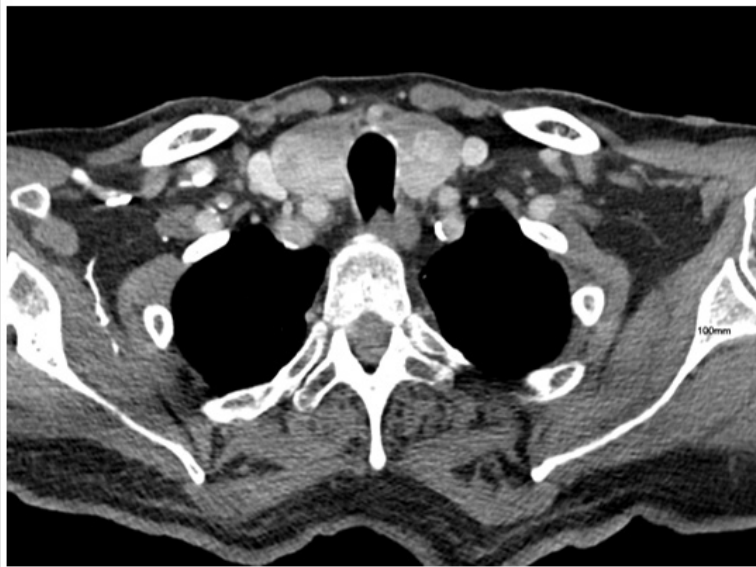

Figure 2: CT of the neck demonstrating no lymphadenopathy or areas concerning for metastases.

On day 8, the patient was more somnolent, had involuntary jerking, and was found to be tachycardic and hypertensive. He was switched to IV metoprolol 10 mg and continued on methimazole 20 mg PO three times daily. His IV metoprolol dose was increased to 10 mg IV 4 times daily the next day to manage his persistent tachycardia and atrial fibrillation. Endocrinology was also consulted and recommended continued methimazole and beta-blocker therapies. On day 10 of the patient's admission, the patient began to recognize family members, was more cooperative, but was still somewhat confused. He converted to normal sinus rhythm that night and was switched to diltiazem 60 mg PO three times daily and metoprolol 50 mg every 6 hours the next day. Unfortunately, the patient converted back to atrial fibrillation with RVR later that night. He was switched back to metoprolol 10 mg IV and was back in normal sinus rhythm with frequent premature atrial complexes on day 13 of his admission. He was then switched back to metoprolol 50 mg every 6 hours. He also demonstrated increased episodes of clarity per family. He continued in this fashion until day 15 when he was transferred to another floor in the hospital and missed a dose of metoprolol, causing him to convert back to atrial fibrillation with RVR. This was treated with another course of IV metoprolol. He also became agitated and confused which was again treated with Haldol. Psychiatry observed continued delirium despite improvement in his thyroid hormone levels, even exhibiting occasional hallucinations (Table 1). He was cleared by psychiatry at this time with recommendations for thyroidectomy or radioactive iodine ablation to ultimately treat his delirium secondary to thyrotoxicosis. Final mental status examination is as follows:

Table 1: Thyroid hormone levels during patient's hospital admission.

Inpatient Day	TSH	total T3	free T3	free T4
2	0.006			>7.77
9			9.7	5.33
12	<0.005			2.82
15				2.07
21	0.009		3	1.33

Mental Status Exam

- a. **Vitals:** T - 36.5, HR - 135, RR - 20, BP - 116/86, SpO₂ - 95%
- b. **Appearance:** Disheveled
- c. **Behavior/Motor Activity:** Psychomotor retardation
- d. **Musculoskeletal:** Observed muscle strength/tone within normal limits
- e. **Gait/Station: Other:** Not observed
- f. **Speech:** Normal
- g. **Mood:** Fair
- h. **Affect:** Mildly constricted
- i. **Thought Process/Associations:** Loose associations
- j. **Thought Content:** Distorted
- k. **Cognition/Attention/Memory/Concentration:** Disoriented, Inattentive during the interview and requires redirection
- l. **Insight:** Poor
- m. **Judgment:** Poor
- n. **Language:** Within normal limits
- o. **Fund of Knowledge:** Other: Limited

By day 16, he demonstrated sinus bradycardia with frequent premature atrial complexes with metoprolol adjustments to 75 mg PO every 6 hours. On day 18 of the patient’s admission, he suffered a fall and a CT of the head demonstrated “atrophy and chronic small vessel ischemic change with no acute intracranial findings.” The patient continued to demonstrate stable heart rate, rhythm, and blood pressure with normalization of his thyroid hormone levels on methimazole therapy. Ultimately, the patient was deemed medically stable to be transferred to a skilled nursing facility with follow ups with his PCP, cardiologist, general surgeon, and endocrinologist on an outpatient basis. During his course, he demonstrated significant lability in his heart rate and blood pressure that were finally well controlled on beta-blocker therapy (Figures 3 & 4). He was discharged on the following medications:

- Methimazole 5 mg, 2 tablets, PO BID
 - Metoprolol 50 mg Q6H. vitamin D3 PO daily
 - Folic acid 1 mg PO daily
 - Seroquel 50 mg PO QHS (for sundowning)
 - Xarelto 20 mg PO with supper
 - Rosuvastatin 40 mg PO daily
 - Thiamine 100 mg PO daily
- His final physical examination is as follows:

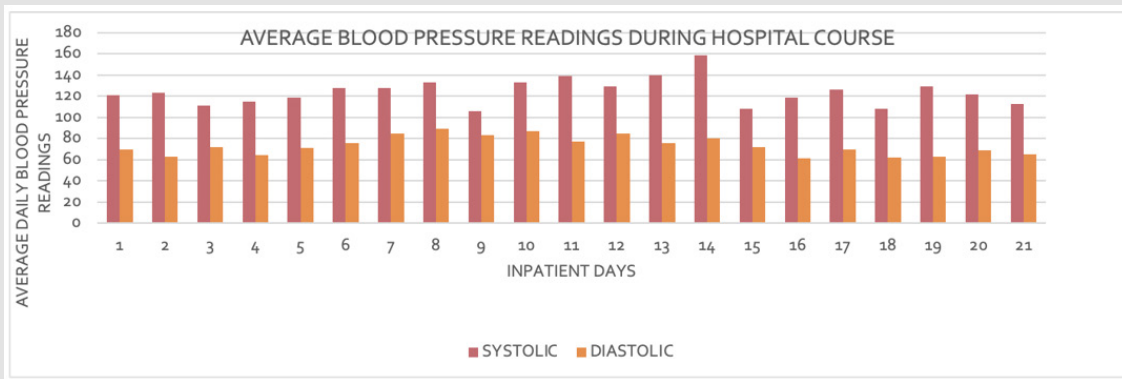


Figure 3: Average blood pressure readings during patient’s hospital admission.

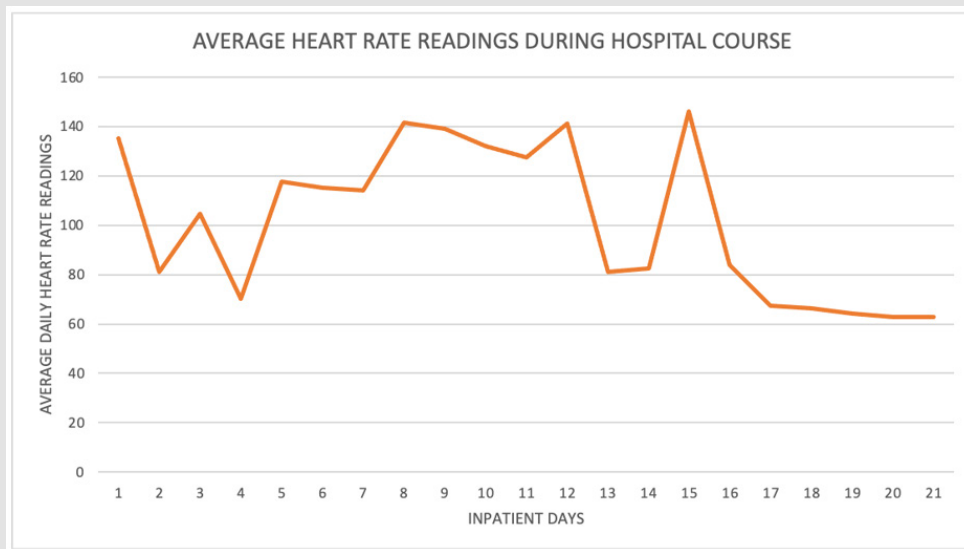


Figure 4: Average heart rate readings during patient’s hospital admission.

Physical Examination

Vitals: T - 36.6°C (Oral), TMIN - 36.4°C (Oral), TMAX - 36.8°C (Oral), HR - 63(Monitored), RR - 16, BP - 113/65, SpO2 - 98%

Current Measurements

HT: 172.7 cm WT: 74.0 kg IBW: 68.38 kg BSA: 1.95 m² BMI: 26.5

- **Constitutional:** Alert, pleasant, cooperative.
- **Head:** Normocephalic, atraumatic.
- **Eyes:** Extraocular movement intact, sclerae anicteric.
- **ENT:** Moist mucous membranes, no lesions.
- **Neck:** Supple, Trachea Midline, No Thyromegaly, No Masses, Full Rom.
- **Respiratory:** Clear to auscultation bilaterally, no wheezing or rales.
- **Cardiovascular:** Regular rate and rhythm, S1, S2, no gallops.
- **Gastrointestinal:** Soft, nontender, nondistended, normoactive bowel sounds.
- **Musculoskeletal/Extremities:** No pedal edema, no cyanosis, no clubbing.
- **Skin:** Normal temperature, turgor and texture, intact.

Discussion

Thyroid Storm is a thyrotoxicosis crisis resulting in an acute hypermetabolic syndrome requiring emergency intervention. The mortality rate has been reported to be 9.5-11% [1]. Diagnostic criteria for thyrotoxicosis can vary, but typically include CNS involvement such as delirium and one of the following, fever, tachycardia, CHF, and/or GI complications [2]. In our case, the patient had a persistent delirium along with unrelenting tachycardia complicated by new onset afib with rvr. Thyroid storm is often diagnosed by as a combination of thyroid function studies showing low to undetectable thyroid stimulating hormone (TSH) (<0.01mU/L) with elevated free thyroxine (fT4) and/or free triiodothyronine (fT3), positive thyroid receptor antibody (TRab) (if the underlying etiology is Graves' disease), along with clinical signs and symptoms of end organ damage [3]. The differential diagnosis include TSHomas (pituitary adenomas), thyroid cancers, iatrogenic (noncompliance with anti-thyroid medication), Grave's Disease, diabetic ketoacidosis, severe emotional stress, trauma, surgery, radioiodine therapy, and pregnancy/delivery [4].

For example, Naito and others report a case where a patient developed thyrotoxicosis after a significant burn injury. Trauma such as burns or extensive surgery has the potential to suppress host tumor immunity. This can result in exponential growth of carcinoma tissue in cancer patients [5]. In our case, the patient had a biopsy confirmed

follicular neoplasm of the thyroid gland. Hyperfunctioning thyroid cancer can absorb iodine while synthesizing thyroid hormone. Mutations in TSH receptor genes activate the intracellular cyclic adenosine monophosphate (cAMP) cascade downstream. This seems to be the most likely cause of hyperthyroidism in thyroid cancer [6]. Among hyperthyroid cancers, follicular thyroid carcinoma (FTC) has a significantly higher prevalence (46.5% for primary and 71.4% for metastatic disease) than other types of thyroid cancers [7]. However, The Surveillance, Epidemiology and End Results (SEER) cancer registry (1974–2013) conveys that FTC only accounts for 10.8% of all thyroid cancers, making it a relatively rare form of cancer [8]. Takedani and others provided a table of case reports summarizing incidences of hyperthyroid thyroid cancers in Japan, totaling only six in their review, and included papillary thyroid carcinoma (PTC), follicular variant of PTC, FTC, and anaplastic thyroid carcinoma (ATC) [9].

Once diagnosed, all patients with thyroid would benefit from admission the ICU for aggressive medical management to address end organ affects and to attain euthyroid state [3]. Initial treatment is a chemical bridge (medical management achieving euthyroid state) to the definitive treatment which is thyroidectomy or radioactive iodine ablation [3]. First-line treatments include propylthiouracil (PTU), carbimazole, and methimazole (MMI), which are antithyroid medications that inhibit thyroid hormone synthesis through their action on the thyroid peroxidase enzyme [10]. PTU antagonizes the peripheral conversion of T4 to T3 by inhibiting type-1 deiodinase. PTU is preferred over MMI due to its effects on peripheral conversion and has greater efficacy in lowering serum T4 and T3 within 24 hours compared to MMI [11]. Moreover and notable, PTU is preferred over methimazole in the first trimester due to increased risk of birth defects [10]. PTU is dosed at a 500–1000 mg load, then 250 mg every four hours, which can be given orally or intravenously. The recommended maximum dose of PTU is 1600 mg per day. MMI is dosed at 60–80 mg/day, with maximal dose of 100 mg/day [11]. The major adverse reactions to PTU and MMI include agranulocytosis, hepatotoxicity, and ANCA positive vasculitis [10]. Of note, and pertinent to thyroid cancers, chronic use of MMI agents have shown to induce TSHoma (pituitary) enlargement by a negative feedback mechanism that follows a decrease in thyroid hormone concentrations [12].

Our case received MMI rather than PTU for unclear reasons. It is possible that our hospitalist team was more familiar with MMI rather than PTU and we unfortunately did not have access to endocrine consultation. Potassium iodide (KI) utilized with anti-thyroid drugs is generally the gold standard treatment for thyroid crisis cases [13]. Iodine acts to inhibit thyroid hormone via the "Wolff-Chaikoff effect." This effect essentially reduces hormone biosynthesis by inhibition of iodine organification [14]. Iodine is also helpful from a preoperative adjunctive as it decreases gland vascularity and blood loss [15]. Although, it should be noted that there is a paucity of information as to whether KI is effective with thyroid cancer induced thyroid storm and could possible exacerbate the patient's condition by elevating thyroid

hormone via increase availability of substrate [3]. Dosing of potassium iodide is either 5–7 drops (0.25–0.35 mL) of Lugol’s solution (8 mg iodide/drop) or 1–2 drops (0.05–0.1 mL) of saturated solution potassium iodide (SSKI) (50 mg iodide/drop) three times daily mixed in water or juice for 10 days before surgery. Up to 200mg/day of total iodine can be administered, with higher doses given to patients with suspected decreased gastrointestinal absorption [11]. Adverse effects are many and include symptoms across systems including GI and neurological symptoms. As KI and MMIs remains somewhat controversial in thyroid cancer induced hyperthyroid state, one can consider an altogether different class of medications, the somatostatins.

Somatostatins have proven to be effective in managing both TSHomas of the pituitary and GH secreting adenomas [16]. As TSHomas ex-

press somatostatin receptors, treatment with somatostatin analogues is effective for hormonal control and tumor shrinkage [17]. Noriaki Fukuhara and others sought to treat several cases of TSHomas with octreotide and tabulated the outcome results. In their series of cases, octreotide resulted in normalizing hormone levels in 84% of the cases while tumor shrinkage occurred in 61% of cases [18]. Unfortunately, I could not find the use of octeotride to treat follicular neoplasm of the thyroid when perusing the literature. Other adjunctive measures for the treatment of thyroid storm include Lithium, Potassium Perchlorate, Glucorticoids, Cholestyramine, and Plasmapheresis. Figure one below is adapted from Vinen-Vega, et al, but is limited by the fact that somatostatin therapy is not included in the algorithm [19] (Figure 5).

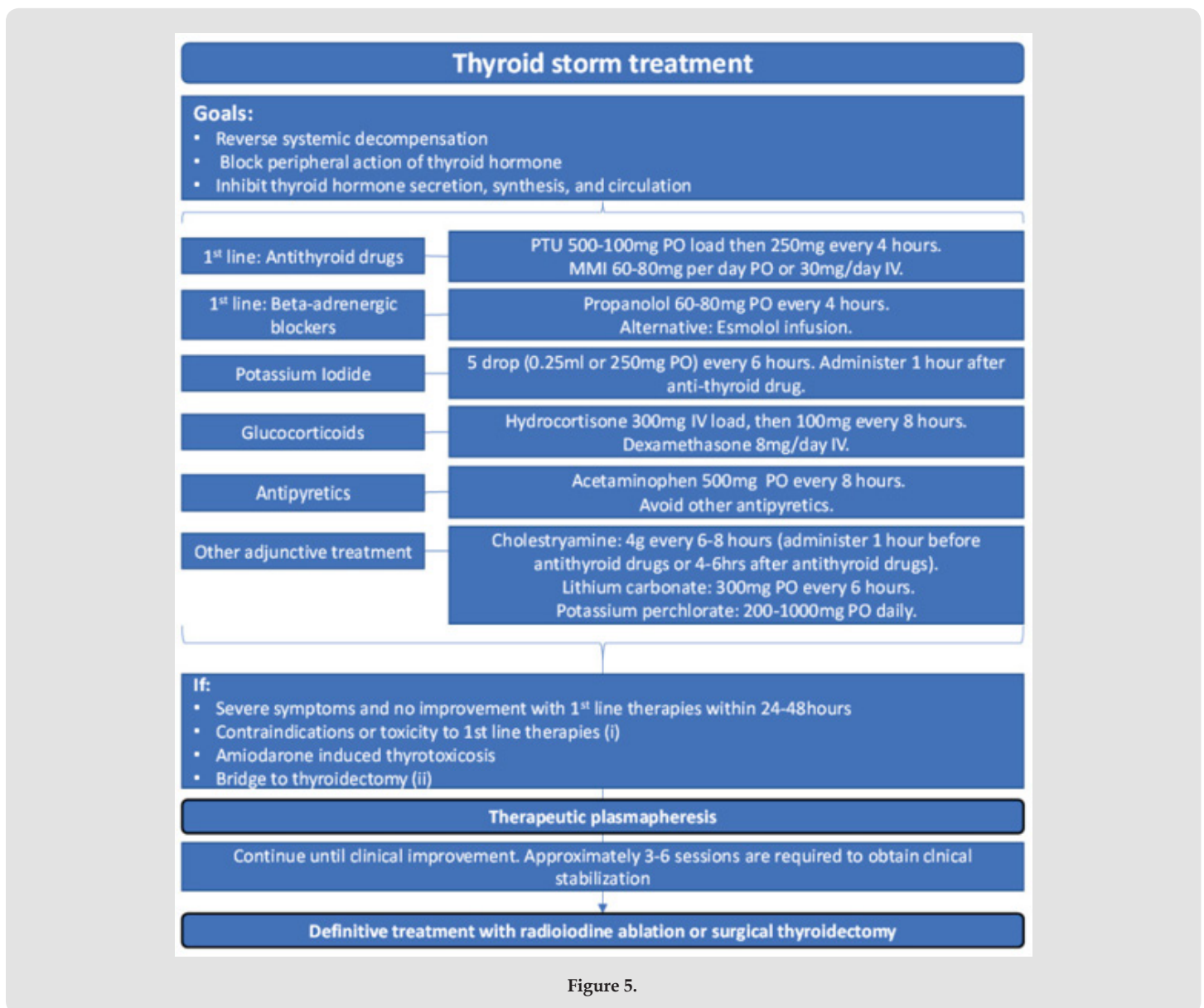


Figure 5.

In conclusion, our case was not a TSHoma, but rather a FTC of the thyroid producing a thyroid crisis. It was managed by methimazole and beta blockade for the adverse cardiac effects. Surgery was consulted, but unfortunately, the patient's cardiac dynamics never stabilized to the degree where it was deemed safe to proceed with thyroidectomy. After the patient's thyroid levels normalized and cardiac dynamics stabilized, the patient was discharged to rehabilitation with endocrine follow-up. He was lost to our follow-up as well. The consult & liaison psychiatrist can contribute to the overall care for the patient by yes recognizing delirium and assisting in the management of delirium associated agitation, but also with helpful reminders concerning evidence based treatment to achieve a euthyroid state for the definitive treatment of thyroidectomy or radioactive ablation. In retrospect, I do wonder if our patient would have benefited from PTU or even Octeotide therapy. It is important to obtain endocrine and oncology consultation and support when considering such agents in the treatment of thyroid storm.

References

1. Wartofsky L (2012) Clinical criteria for the diagnosis of thyroid storm. *Thyroid* 22: 659-660.
2. Akamizu T, Satoh T, Isozaki O, Suzuki A, Wakino S, et al. (2012) Diagnostic criteria, clinical features, and incidence of thyroid storm based on nationwide surveys. *Thyroid* 22: 661-679.
3. De Almeida, Reuben, cabandugama (2022) Clinical Review and Update on the Management of Thyroid Storm. *Missouri medicine* 119(4): 366-371.
4. Fujio Shingo, Ashari, Mika Habu, Hitoshi yamahata, Moinuddin FM, et al. (2014) Thyroid Storm induced by TSH-secreting pituitary adenoma: a case report. *Endocrine Journal* 61(11): 1131-1136.
5. Yoshiyuki Naito, Tetsuhiro Sone, Kazuya Kataoka, Masaki Sawada, Kazuo Yamazaki (1997) Thyroid Storm Due to Functioning Metastatic Thyroid Carcinoma in a Burn Patient. *Anesthesiology* 87(2): 433-435.
6. Gozu H, Avsar M, Bircan R, Sahin S, Ahiskanali R, et al. (2004) Does a Leu 512 Arg thyrotropin receptor mutation cause an autonomously functioning papillary carcinoma? *Thyroid* 14(11): 975-80.
7. Liu J, Wang Y, Da D, Zheng M (2019) Hyperfunctioning thyroid carcinoma: a systematic review. *Mol Clin Oncol* 11(6): 535-550.
8. Lim H, Devesa SS, Sosa JA, Check D, Kitahara CM (2017) Trends in thyroid Cancer incidence and mortality in the United States, 1974-2013. *JAMA* 317(13): 1338-1348.
9. Takedani K, Notsu M, Adachi N, Sayuri T, masahrriro Y, et al. (2021) Thyroid crisis caused by metastatic thyroid cancer: an autopsy case report. *BMC Endocr Disord* 21: 213.
10. Abdi H, Amouzegar A, Azizi F (2019) Antithyroid drugs. *Iran J Pharm Res* 18(Suppl1): 1-12.
11. Ross DS, Burch HB, Cooper DS, M C Greenlee, Laurberg P, et al. (2016) American Thyroid Association guidelines for diagnosis and management of hyperthyroidism and other causes of thyrotoxicosis. *Thyroid* 26(10): 1343-1421.
12. Beck-Peccoz P, Persani L, Mannavola D, Campi I (2009) Pituitary tumours: TSH-secreting adenomas. *Best Pract Res Clin Endocrinol Metab* 23: 597-606.
13. Akamizu T (2018) Thyroid Storm: A Japanese Perspective. *Thyroid* 28(1): 32- 40.
14. Chung HR (2014) Iodine and thyroid function. *Ann Pediatr Endocrinol Metab* 19(1): 8-12.
15. Huang SM, Liao WT, Lin CF, Sun HS, Chow NH (2016) Effectiveness and mechanism of preoperative lugol solution for reducing thyroid blood flow in patients with euthyroid graves' disease. *World J Surg* 40(3): 505-509.
16. Socin HV, Chanson P, Delemer B, Tabarin A, Rohmer V, et al. (2003) The changing spectrum of TSH-secreting pituitary adenomas: diagnosis and management in 43 patients. *Eur J Endocrinol* 148: 433-442.
17. Gatto F, Barbieri F, Castelletti L, Arvigo M, Pattarozzi A, et al. (2011) *In vivo* and *in vitro* response to octreotide LAR in a TSH-secreting adenoma: characterization of somatostatin receptor expression and role of subtype 5. *Pituitary* 14: 141-147.
18. Noriaki Fukuhara, Kentaro Horiguchi, Hiroshi Nishioka, Hisanori Suzuk, Akira Takeshita, et al. (2015) Short-term preoperative octreotide treatment for TSHsecreting pituitary adenoma. *Endocrine Journal* 62(1): 21-27.
19. Vinan-Vega M, Mantilla B, Jahan N, C Peminda, K Nugent, et al. (2020) Usefulness of plasmapheresis in patients with severe complicated thyrotoxicosis. *Proc (Bayl Univ Med Cent)* 34(2): 279-282.

ISSN: 2574-1241

DOI: 10.26717/BJSTR.2023.53.008410

T Patrick Jensen. Biomed J Sci & Tech Res



This work is licensed under Creative Commons Attribution 4.0 License

Submission Link: <https://biomedres.us/submit-manuscript.php>



Assets of Publishing with us

- Global archiving of articles
- Immediate, unrestricted online access
- Rigorous Peer Review Process
- Authors Retain Copyrights
- Unique DOI for all articles

<https://biomedres.us/>