

Late Infectious Complications in Solid Organ Transplant: Disseminated Aspergillosis and Pulmonary Tuberculosis in a Patient with Kidney Transplant

Jorge Fernando Topete Reyes*, José Jaime Gutiérrez Pérez, Aragaki Yuritomo, Rubén Lara Monterrubio, Hugo Bonifacio Espinoza, Juan Oziel Romero Tafoya, Reyes Martínez Diana María, Denisse Arellano Méndez, Renato Parra Michel and Javier Soto Vargas

Medical Chief in Nephrology Department in General Regional Hospital N°46 Lazaro Cardenas of the Mexican Institute of Social Security, México

***Corresponding author:** Jorge Fernando Topete Reyes, Medical Chief in Nephrology Department in General Regional Hospital N°46 Lazaro Cardenas of the Mexican Institute of Social Security, Calz. Lázaro Cárdenas 2063, 8 de Julio, 44910 Guadalajara, Jal, México

ARTICLE INFO

Received: 📅 September 12, 2023

Published: 📅 September 20, 2023

Citation: Jorge Fernando Topete Reyes, José Jaime Gutiérrez Pérez, Aragaki Yuritomo, Rubén Lara Monterrubio, Hugo Bonifacio Espinoza, Juan Oziel Romero Tafoya, Reyes Martínez Diana María, Denisse Arellano Méndez, Renato Parra Michel and Javier Soto Vargas. Late Infectious Complications in Solid Organ Transplant: Disseminated Aspergillosis and Pulmonary Tuberculosis in a Patient with Kidney Transplant. Biomed J Sci & Tech Res 52(5)-2023. BJSTR. MS.ID.008327.

Background

Infections due to opportunistic organisms are an important cause of morbidity and mortality in kidney transplant recipients. The risk of infections depends on various factors such as the time after transplantation, the degree of immunosuppression and exposure to infectious pathogens. Opportunistic infections due to tuberculosis and concomitant aspergillosis are rare presentations [1,2].

Case Report

A 31-year-old female patient with a history of chronic kidney disease who received a kidney transplant from a brain-dead donor 5 years ago, classified as having a high immunological and infectious risk post-transplant, currently with immunosuppressive treatment with tacrolimus, mycophenolic acid and prednisone. Important past history, she presented early CMV infection, in addition to Banff 1A cellular rejection one year after the transplant. She was admitted due to the presence of fever, asthenia, adynamia, unintentional weight loss, generalized lymph nodes with increased lymph nodes in the neck, ax-

illary region and groin within 1 month of evolution. Other medical history of importance: hypertension and human papillomavirus infection (resolved).

Physical Exam

Alert, regular general conditions, normal vital signs, at the time of evaluation without fever or oxygen desaturation, erythematous pharynx, presence of lymph node chains in the cervical, axillary and bilateral inguinal region with the presence of indurated, mobile, painful lymph nodes at palpation and mobilization, on auscultation with decreased murmur, without crackles or wheezing, assignological abdomen, extremities without edema.

Clinical Evolution

Due to the clinical presentation and the use of immunosuppression therapy, the febrile syndrome and generalized lymphadenopathy were our main key points to approach, with evidence of disseminated aspergillosis infection in excisional biopsy of inguinal lymph nodes

and pulmonary tuberculosis due to *M. Tuberculosis* by BARR staining in sputum. Treatment was started with voriconazole and second-line antifungals due to pharmacological interaction between rifampicin, voriconazole and tacrolimus. The fever and nocturnal diaphoresis subsided 48-72 hours after starting treatment, and discharge from the hospital was decided in the following days. Immunosuppressive

treatment was not suspended because there were no signs of hemodynamic instability or signs of respiratory distress. There was a need to reduce the dose of the calcineurin inhibitor due to supratherapeutic levels in the blood. During outpatient follow-up, the patient maintains stable renal function and adequate levels of immunosuppression (Figures 1 & 2).

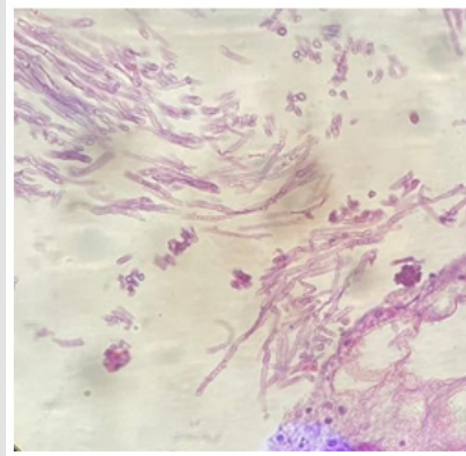


Figure 1: Inguinal lymph node biopsy showing fungal hyphae with dichotomous branches (hematoxylin and eosin stain).

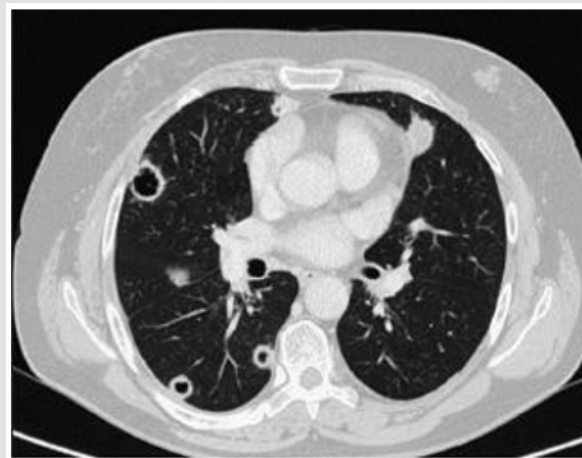

Figure 2: Chest computed axial tomography showing multiple cavitated lesions.

Discussion

Infections remain one of the main complications after kidney transplantation, along with cardiovascular and neoplastic disease [1-4]. Anti-rejection immunosuppressive management composed of a calcineurin inhibitor, antimetabolite and steroid interfere with the normal function of neutrophils and immune responses mediated by T and B cells, increasing the risk of viral, fungal and bacterial infections in the patient with kidney transplant [2,5]. Infectious complications

are classified according to temporality into: early post-transplant infections (0 to 30 days), infections during the first year post-transplant (31 to 365 days) and late onset (>365 days). In the early period, nosocomial infections stand out, those derived from the donor or the recipient. In the period when immunosuppression levels are at its highest (31 days to 1 year) there is a greater risk of opportunistic infections, some may be susceptible to prophylaxis treatment according to the infectious risk; and in the late period (>1 year) infections acquired in the community stand out, without ruling out

endemic and opportunistic microorganisms [1,3,6,7]. Tuberculosis represents a potentially fatal infectious complication in immunosuppressed patients. In recipients of solid organ transplants, the risk is up to 70 times higher compared to the general population. Reactivation of latent tuberculosis in organ transplant recipients within the first twelve months is the most common manifestation, hence the importance of screening prior to transplantation. Findings are quite nonspecific, they may include fever, nocturnal diaphoresis, unintentional weight loss, or cough. Diagnosis remains complicated and often delayed, leading to a more severe course of the disease. Treatment is challenging due to drug interactions and side effects as presented in this case. As for fungal infections, they represent less than five percent of all infections in kidney transplant patients, with *Aspergillus* being a frequent agent after *Candida* spp. Major risk factors include advanced age, diabetes mellitus, delayed graft function, acute graft rejection, chronic obstructive pulmonary disease, cytomegalovirus disease, and neutropenia. The risk of *Aspergillus* has been noted to occur in the first 6 months after transplant, however, the risk may be present if patients experience ongoing rejection episodes. The form of presentation can be necrotizing and rapidly progressive pneumonia along with cavitation, vascular invasion and hemorrhagic infarctions and sometimes present non-specific symptoms [8,9]. Impaired T cell response increases the risk of tuberculosis throughout the allograft life span. Impaired neutrophil action and lung structural defects in patients with tuberculosis also increase the possibility of aspergillo- sis infection, making it possible to have both infections. Coinfections of aspergillo- sis and tuberculosis have been described [3,5].

In the case of our patient, the chest CT showed cavitated lesions. Acid-fast bacilli were identified in serial Ziehl-Neelsen staining of sputum, and disseminated aspergillo- sis was reported in the inguinal lymph node biopsy. One of the most important limitations in our environment is that we do not count with molecular or serological diagnostic tests such as Gene-Xpert or Galactomannan. The diagnoses were supported by the available microbiology, suggestive radiological findings, histopathology and the high prevalence of these diseases in our population. Treatment with voriconazole and second-line anti- fomic treatment, with isoniazid, ethambutol, pyrazinamide and moxi- floxacin (replacing rifampicin due to its interaction with voriconazole and tacrolimus) was initiated. After starting treatment, the fever and nocturnal diaphoresis resolved, kidney function has been stable and adequate levels of immunosuppression have been met after reducing the calcinerin inhibitor dosage by 25%, achieving tacrolimus blood levels of between 7 to 9 ng/dl.

Conclusion

The coexistence of pulmonary tuberculosis and extrapulmonary disseminated aspergillo- sis is very rare. Tuberculosis with multiple cavitated lung lesions and the presence of aspergillomas is reported more frequently in the literature, however, invasive aspergillo- sis and tuberculosis are life-threatening opportunistic infections in immuno- compromised patients that may cause serious adverse events in the absence of timely diagnosis and appropriate treatment. Close moni- torization of immunosuppression levels should be performed due to the complex interaction of voriconazole and tacrolimus.

References

1. Agrawal Akansha, Ison Michael G, Danziger-Isakov Lara (2022) Long-term infectious complications of kidney transplantation. *CJASN* 17(2): 286-295.
2. Vidanapathirana M, Minuvanpitiya G, Karunaratne R, Fernando A (2021) Triple infection with disseminated tuberculosis, invasive aspergillo- sis and COVID-19 in an organ transplant recipient with iatrogenic immunosup- pression. *BMJ Case Rep* 14(8): e245131.
3. Cikova A, Vavrincova-Yaghi D, Vavrinc P, Dobisova A, Gebhardtova A, et al. (2017) Gastrointestinal tuberculosis following renal transplantation ac- companied with septic shock and acute respiratory distress syndrome: a survival case presentation. *BMC Gastroenterol* 17(1): 131.
4. Dissanayake HA, Weeratunga PN, Karunanayake P, Lanerolle RD, Chandu de Silva MV, et al. (2018) Embolizing pulmonary aspergillo- sis, mycobac- terial & aspergillo- sis splenic abscess and cytomegalovirus co-infection following steroid induced immunosuppression: a case report. *BMC Infect Dis* 18(1): 367.
5. Sigera LSM, Denning DW (2023) Invasive Aspergillo- sis after Renal Trans- plantation. *J Fungi (Basel)* 9(2): 255.
6. Balcan B, Ozcelik U, Ugurlu AO, Aydin M, Nalcaci S, et al. (2018) Increased Mortality Among Renal Transplant Patients With Invasive Pulmonary As- pergillo- sis Infection. *Prog Transplant* 28(4): 349-353.
7. Fishman JA (2007) Infection in solid-organ transplant recipients. *N Engl J Med* 357: 2601-2614.
8. Seok H, Huh K, Cho SY, Kang CI, Chung DR, et al. (2020) Peck KR Factores de riesgo para el desarrollo y la mortalidad de la aspergillo- sis pulmonar invasiva en receptores de trasplantes de riñón. *EUR. J.Clin. Microbiol. In- fectar* 39: 1543-1550.
9. Trnacevic S, Mujkanovic A, Nislic E, Begic E, Karasalihovic Z, et al. (2018) Halilovic MA Aspergillo- sis invasiva después del trasplante de riñón: enfo- que de tratamiento. *Medicina. Arco* 72: 4560-458.

ISSN: 2574-1241

DOI: 10.26717/BJSTR.2023.52.008327

Jorge Fernando Topete Reyes. Biomed J Sci & Tech Res



This work is licensed under Creative Commons Attribution 4.0 License

Submission Link: <https://biomedres.us/submit-manuscript.php>



Assets of Publishing with us

- Global archiving of articles
- Immediate, unrestricted online access
- Rigorous Peer Review Process
- Authors Retain Copyrights
- Unique DOI for all articles

<https://biomedres.us/>