

Clangorous and Inbred-High Grade Squamous Intraepithelial Lesion-Uterine Cervix

Anubha Bajaj*

Consultant Histopathologist, A.B. Diagnostics, A-1, Ring Road, Rajouri Garden, New Delhi 110027, India

***Corresponding author:** Anubha Bajaj, Consultant Histopathologist, A.B. Diagnostics, A-1, Ring Road, Rajouri Garden, New Delhi 110027, India

ARTICLE INFO

Received: 📅 August 10, 2023

Published: 📅 August 25, 2023

Citation: Anubha Bajaj. Clangorous and Inbred-High Grade Squamous Intraepithelial Lesion-Uterine Cervix. Biomed J Sci & Tech Res 52(3)-2023. BJSTR. MS.ID.008257.

ABSTRACT

Abbreviations: HSIL: High Grade Squamous Intraepithelial Lesion; HPV: Human Papilloma Virus; CIN II: Cervical Intraepithelial Neoplasia Grade II; LSIL: Low Grade Squamous Intraepithelial Lesion; HIV: Human Immunodeficiency Virus; HPV: Human Papilloma Virus; RB: Retinoblastoma Protein

Editorial

High grade squamous intraepithelial lesion (HSIL) is designated as a precancerous, proliferative lesion incriminating stratified squamous epithelial layer of uterine cervix. Lesion represents with variable proportionate cytoplasmic maturation and nuclear atypia involving comprehensive squamous epithelial cell layers. High risk variants of human papilloma virus (HPV) contribute to disease emergence, especially HPV16. Cervical intraepithelial neoplasia grade II (CIN II) exhibits maturation within superficial cytoplasmic surface and is associated with significant proportionate lesion regression. Cervical intraepithelial neoplasia grade III (CIN III) is comprised of significant nuclear atypia which comprehensively incriminates entire thickness of squamous epithelial cell layer and loss of surface maturation. Lesion is preponderantly associated with possible progression into invasive squamous cell carcinoma of uterine cervix. Implicated squamous epithelial cells display diffuse, intense nuclear and cytoplasmic immunoreactivity to p16, which demonstrates block subtype of immunostaining. However, pertinent p16 immunohistochemistry is prone to unwarranted utilization or misinterpretation with consequently augmented diagnosis of high grade squamous intraepithelial

lesion (HSIL). Recommended therapeutic strategy is surgical extermination of lesion. However, surgical eradication is to be circumvented in pregnant subjects, instances with cervical intraepithelial lesion grade III (CIN III) or disease incrimination within females < 25 years old.

Squamous intraepithelial lesion of uterine cervix is graded as ~low grade squamous intraepithelial lesion (LSIL) ~high grade squamous intraepithelial lesion (HSIL) [1,2]. High grade squamous intraepithelial lesion is subdivided into ~cervical intraepithelial neoplasia grade II (CIN II) which is associated with significant proportionate lesion retrogression. CIN II exhibits cytoplasmic maturation confined to upper third of stratified squamous epithelial mucosa layering uterine cervix. ~cervical intraepithelial neoplasia grade III (CIN III) is especially encountered in young women. CIN III delineates diffuse, basal and parabasal subtypes and appears devoid of maturation comprehensively across stratified squamous epithelial cell layers [1,2]. High grade squamous epithelial lesion (HSIL) commonly incriminates women within reproductive age group and demonstrates an estimated prevalence of up to 1%. Characteristically, high grade squamous intraepithelial lesion (HSIL) occurs within older subjects,

in contrast to low grade squamous epithelial lesion (LSIL). Factors contributing to occurrence of high grade squamous intraepithelial lesion (HSIL) appear as infection with human immunodeficiency virus (HIV), immunosuppression or tobacco consumption as cigarette smoking [2,3]. High grade squamous intraepithelial lesion (HSIL) predominantly arises within transformation zone and implicates cells configuring squamo-columnar junction or columnar epithelial cells. High grade squamous intraepithelial lesion (HSIL) is associated with high-risk variants of human papilloma virus (HPV) which induce clonal proliferation of stratified squamous epithelial cells. Viral E6 protein appears adherent to p53 tumour suppressor protein with consequent occurrence of protein degradation [3,4].

Viral E7 protein induces inactivation of retinoblastoma protein (Rb), thereby engendering cell cycle progression. Functioning viral E7 protein triggers upregulation of tumour suppressor gene CDKN2A with significant accumulation and overexpression of p16. Extracellular E7 implicates endothelial cells due to enhanced production of interleukins 6 and 8 (IL6 and IL8), thereby augmenting progression into invasive carcinoma of uterine cervix [2,3]. Generally, high grade squamous intraepithelial lesion (HSIL) is engendered due to high-risk subtypes of human papilloma virus (HPV), commonly subtypes 16, 18, 45, 31, 33, 52, 58 and 35 in decreasing order of frequency. High risk variants 16 and 18 induce up to 60% of high grade squamous intraepithelial lesions (HSIL) [2,3]. High grade squamous intraepithelial lesion (HSIL) is an asymptomatic disease arising within females of reproductive age group. Upon colposcopy, foci of leucoplakia, mosaic pattern, vascular alterations, and whitish epithelium upon exposure to acetic acid may be discerned [3,4]. Cytological examination exhibits enhanced nucleocytoplasmic (N/C) ratio, nuclear enlargement of up to three times, hyperchromatic nuclei, coarse chromatin with irregular nuclear membrane and inconspicuous nucleoli. Tumour cells may configure a syncytium, crowded groups, cellular clusters or disseminated singular cells permeated with hyperchromatic nuclei. Upon gross examination, lesion preponderantly appears as 'flat' wherein

discernment may be challenging in the absence of acetic acid application [3,4].

Upon microscopy, the conventional or classic configuration is comprised of cellular atypia and nuclear anomalies as hyperchromatic nuclei, coarse nuclear chromatin, irregular nuclear contour, and inconspicuous nucleoli comprehensively within entire epithelial thickness of uterine cervix. Besides, elevated nucleocytoplasmic ratio occurs within cells confined to lower two/ thirds of stratified squamous epithelium. Cervical intraepithelial neoplasia II (CIN II) exhibits cytoplasmic maturation within upper one third of stratified cervical epithelial mucosa. Cervical intraepithelial neoplasia III (CIN III) is accompanied by basal or parabasal subtype with nuclear atypia comprehensively incriminating stratified squamous epithelial cell layer. The stratified epithelium lacks differentiation and maturation across squamous cellular layers.

Mitotic figures are enhanced with discernible atypical mitoses [3,4]. High grade squamous intraepithelial lesion (HSIL) may configure patterns as ~'thin' high grade squamous intraepithelial cell lesion (HSIL) composed of lesions <10 cells thick. The preponderantly focal lesion is concurrent with conventional foci of HSIL and appears reminiscent of atrophy of uterine cervix. ~keratinizing high grade squamous intraepithelial lesion (HSIL) is composed of foci of superficial keratinization in the absence of koilocytosis. ~papillary high grade squamous intraepithelial lesion (HSIL) commonly incriminates endocervical papillae. ~pleomorphic high grade squamous intraepithelial lesion (HSIL) demonstrates foci of bizarre nuclear alterations and multi-nucleation. Lesion may represent as miniature, metaplastic cellular subtype reminiscent of immature metaplastic epithelium [3,4] (Table 1). High grade squamous intraepithelial lesion (HSIL) appears immune reactive to p16 which demonstrates an intense, diffuse block staining, continuous nuclear or nuclear and cytoplasmic staining confined to basal layer of dysplastic epithelium along with superior expansion [5-8] (Figures 1 & 2).

Table 1: Differentiation between HSIL with glandular involvement and glandular lesion [4].

Cytological Features	HSIL with Glandular Involvement	Glandular Lesion
Architecture	Syncytial clusters	Loss of honeycomb pattern
	Peripheral nuclear flattening	Loss of nuclear polarity
	Central whirling	Nuclear crowding with overlapping
Nuclear Features		
Chromatin pattern	Coarse	Fine
Nuclear grooves	Frequently present	Absent
Nucleoli	Absent	Frequently present
Cytoplasmic Features		
Cytoplasmic processes	Present	Absent
Vacuolation	Absent	Present

Note: HSIL: high grade squamous intraepithelial lesion.

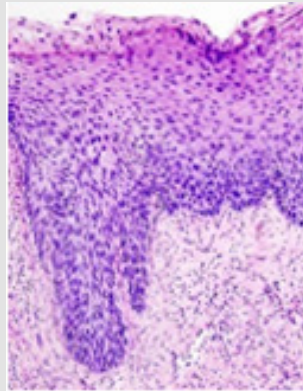


Figure 1: High grade squamous intraepithelial lesion depicting polygonal epithelial cells imbued with abundant, eosinophilic cytoplasm, hyperchromatic nuclei with coarse chromatin and inconspicuous nucleoli along with full thickness nuclear atypia. Several mitotic figures are observed [7].

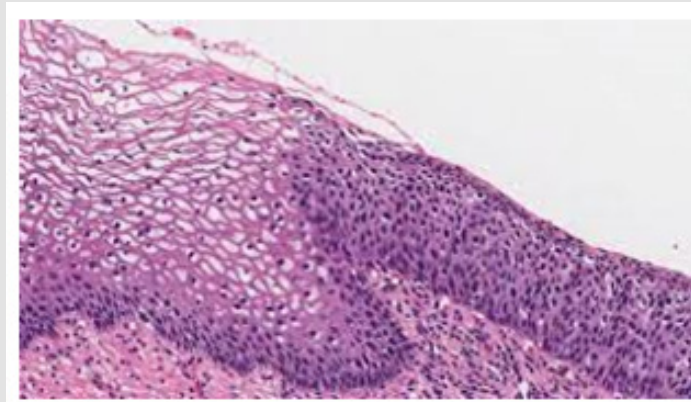


Figure 2: High grade squamous intraepithelial lesion delineating polygonal epithelial cells incorporated with abundant, eosinophilic cytoplasm, hyperchromatic nuclei, coarse chromatin, inconspicuous nucleoli and full thickness nuclear atypia. Mitotic figures are numerous [8].

Immunohistochemistry with p16 may be adopted for ~discernment of high grade squamous intraepithelial lesion (HSIL) from identical lesions as atrophy or immature metaplasia of uterine cervix. ~segregation of morphologically debatable low grade squamous intraepithelial lesion (LSIL) or cervical intraepithelial neoplasia I (CIN I) from cervical intraepithelial neoplasia II (CIN II) on morphological grounds ~controversy within diagnosis of high grade squamous intraepithelial lesion (HSIL). ~surgical tissue samples exemplifying \leq low grade squamous intraepithelial lesion (LSIL) in subjects with misinterpreted high grade squamous intraepithelial lesion (HSIL) upon prior Papanicolaou or human papilloma virus (HPV) evaluation. Lesion is immune reactive to BAG3. Ki67 proliferation index is elevated (5,6). Ribonucleic acid (RNA) in situ hybridization (ISH) for human papilloma virus (HPV) is optimal for detecting E6 / E7 oncoproteins in most instances of high risk and low risk subtypes of human papilloma virus (HPV) [5,6]. Examination of formalin fixed paraffin embedded tissue is significantly sensitive and specific for discerning HPV. Characteristically, staining patterns emerge as ~productive or

proliferative pattern delineating abundant, dense, superficial epithelial nuclear staining along with basal epithelial multiple, dot-like cytoplasmic and nuclear staining. Aforesaid pattern is commonly encountered within low grade squamous intraepithelial lesions (LSIL) or cervical intraepithelial neoplasia I (CIN I) lesions. ~transformative or non-proliferative pattern is comprised of intense, diffuse, multiple dot-like cytoplasmic or nuclear staining whereas intense, superficial nuclear staining may be absent or exceptional [5,6].

Pattern is frequently discerned within cervical intraepithelial neoplasia (CIN III) lesions. ~cervical intraepithelial neoplasia II (CIN II) lesions frequently exhibit a concordance of productive and transformative staining configurations. Aforesaid staining patterns are beneficial in segregating low grade squamous intraepithelial lesions (LSIL) or cervical intraepithelial neoplasia I (CIN I) lesions from identical lesions (5,6). High grade squamous intraepithelial lesion (HSIL) of uterine cervix requires segregation from lesions such as atrophy of uterine cervix, cellular and nuclear atypia of uterine cervix arising due to repair, morphological alterations secondary to radiation ex-

posure, immature squamous metaplasia, transitional metaplasia, or invasive squamous cell carcinoma [5,6].

High grade squamous intraepithelial lesion (HSIL) can be appropriately discerned with cytological assessment with Papanicolaou smear. Besides, surgical tissue sampling of uterine cervix may be obtained for appropriate discernment of the condition [5,6]. Cervical intraepithelial neoplasia grade II (CIN II) is associated with significant proportionate spontaneous regression of ~42% at 12 months and ~50% at 24 months, especially in lesions arising in young women < 30 years. Progression of cervical intraepithelial neoplasia grade II (CIN II) into cervical intraepithelial neoplasia grade III (CIN III) or invasive carcinoma appears enhanced within an extended duration and represents as ~5% at 3 months to ~24% at 36 months [5,6]. Cervical intraepithelial neoplasia grade III (CIN III) is associated with significant progression into invasive squamous cell carcinoma at ~31% in untreated lesions. Besides, lesion displays minimal proportionate spontaneous regression. Proportionate detection of high grade squamous intraepithelial lesion (HSIL) following two consecutive, discernible infections with high-risk variants of human papilloma virus (HPV) appears at ~17%, a figure which enhances to ~41% with two preceding evaluations of high-risk variant 16 of human papilloma virus (HPV) [5,6].

ISSN: 2574-1241

DOI: 10.26717/BJSTR.2023.52.008257

Anubha Bajaj, Biomed J Sci & Tech Res



This work is licensed under Creative Commons Attribution 4.0 License

Submission Link: <https://biomedres.us/submit-manuscript.php>

References

1. Khieu M, Butler SL (2023) High Grade Squamous Intraepithelial Lesion. Stat Pearls International, Treasure Island, Florida.
2. Francoeur AA, Furey KB, Ramirez J, Alexandra M Klomhaus, Christine Holschneider, et al. (2023) Recurrent High-Grade Squamous Intraepithelial Lesion After Loop Excision Procedure Versus Loop Procedure with Top Hat. J Low Genit Tract Dis 27(3): 193-197.
3. Hughes KC, Herring TA, Song JN, Robert V Gately, Lindsey M Przybyl, et al. (2023) Cervical High-Grade Squamous Intraepithelial Lesion Burden and Standard of Care Treatment Effectiveness and Safety in the United States, 2008-2018: The EACH-WOMAN Project. J Low Genit Tract Dis 27(2): 105-112.
4. Shin E, Yu J, Hong SW (2023) Troublemakers in cytologic interpretation of the uterine cervix. J Pathol Transl Med 57(3): 139-146.
5. Foggiatto AI, de Carvalho NS, Fonseca FV, Carlos Afonso Maestri (2023) Recurrence in Cervical High-Grade Squamous Intraepithelial Lesion: The Role of the Excised Endocervical Canal Length-Analysis of 2,427 Patients. J Low Genit Tract Dis 27(1): 1-6.
6. Wei B, Li Q, Seery S, Youlin Qiao, Yu Jiang (2023) Endocervical curettage for diagnosing high-grade squamous intraepithelial lesions or worse in women with type 3 transformation zone lesions: a retrospective, observational study. BMC Womens Health 23(1): 245.
7. Image 1 Courtesy: Libre pathology.
8. Image 2 Courtesy: My pathology report.



Assets of Publishing with us

- Global archiving of articles
- Immediate, unrestricted online access
- Rigorous Peer Review Process
- Authors Retain Copyrights
- Unique DOI for all articles

<https://biomedres.us/>