

# Ingrained and Defiled-Systemic EBV+ T cell Lymphoma of Childhood

Anubha Bajaj\*

Consultant Histopathologist, A.B. Diagnostics, A-1, Ring Road, Rajouri Garden, India

\*Corresponding author: Anubha Bajaj, Consultant Histopathologist, A.B. Diagnostics, A-1, Ring Road, Rajouri Garden, India

## ARTICLE INFO

Received: 📅 July 10, 2023

Published: 📅 July 24, 2023

**Citation:** Anubha Bajaj. Ingrained and Defiled-Systemic EBV+ T cell Lymphoma of Childhood. Biomed J Sci & Tech Res 51(5)-2023. BJSTR. MS.ID.008152.

## ABSTRACT

Systemic EBV+ T cell lymphoma of childhood manifests as a rapidly progressive, life-threatening disorder with a fulminant clinical course. Of obscure aetiology, systemic EBV+ T cell lymphoma of childhood may arise in concurrence with primary Epstein Barr viral infection wherein infiltrating T lymphocytes demonstrate monoclonal rearrangements within T cell receptor (TCR) genes. Systemic EBV+ T cell lymphoma of childhood delineates Epstein Barr virus infected cytotoxic CD8+ T lymphocytes or activated CD4+ T cells and preponderantly incriminates spleen, hepatic or pulmonary parenchyma, lymph nodes, bone marrow or diverse cutaneous surfaces. The rapidly progressive lymphoma condition enunciates multiple organ failure, hemophagocytic lymphohistiocytosis (HLH) and sepsis with antecedent disease associated mortality. Hepatic parenchyma delineates portal and sinusoidal infiltration of neoplastic lymphoid cells, cholestasis, steatosis, and focal necrosis. Lymph node exhibit depletion of B cell areas expanded para-cortical or inter-follicular zones due to infiltrating polymorphous, miniature to intermediate lymphoid cells and enlarged, atypical lymphoid cells with irregular nuclei. Systemic EBV+ T cell lymphoma of childhood is immune reactive to CD2, CD3, CD8 and immune nonreactive to CD56, latent membrane protein 1 (LMP1) and Epstein Barr virus nuclear antigen 2(EBNA2). Majority (100%) of tumour cells exemplify clonal, episomal configuration of wild type, EBV type A or 30bp deleted product of latent membrane protein 1 (LMP1). Therapeutic guidelines are absent and systemic EBV+ T cell lymphoma appears resistant to conventional chemotherapy although hematopoietic stem cell transplant appears advantageous.

## Introduction

Systemic Epstein Barr virus infected (EBV+) T cell lymphoma of childhood manifests as a rapidly progressive, clinically severe, fatal disorder with a fulminant clinical course. Systemic EBV+ T cell lymphoma of childhood follows a primary Epstein Barr viral infection or may arise in concurrence with chronic active Epstein Barr virus infection. As per contemporary World Health Organization (WHO) classification, previously designated lymphoproliferative disorder is currently denominated as systemic EBV+ T cell lymphoma of childhood. Incriminated children and young adults characteristically exhibit monoclonal expansion of Epstein Barr virus (EBV+) infected T lymphocytes demonstrating an activated cytotoxic phenotype. Neoplastic lymphoid cells appear confined to implicated soft tissues or peripheral blood. Lymphoma exemplifies clinical and pathological features concurrent with aggressive NK cell leukaemia. Systemic EBV+ T cell lymphoma of childhood is invariably accompanied by

hemophagocytic lymphohistiocytosis (HLH). Distinction between systemic EBV+ T cell lymphoma of childhood and Epstein Barr virus associated hemophagocytic lymphohistiocytosis (HLH) may be challenging on account of concurrent clinical and histopathological characteristics [1,2]. The lymphoma was previously designated as fulminant EBV+ T cell lymphoproliferative disorder of childhood, sporadic fatal infectious mononucleosis, fulminant hemophagocytic syndrome in children, fatal Epstein Barr virus (EBV) associated hemophagocytic syndrome or severe chronic active Epstein Barr virus (EBV) infection. Severe chronic active Epstein Barr virus infection is denominated as an infectious mononucleosis-like syndrome which persists minimally for 6 months.

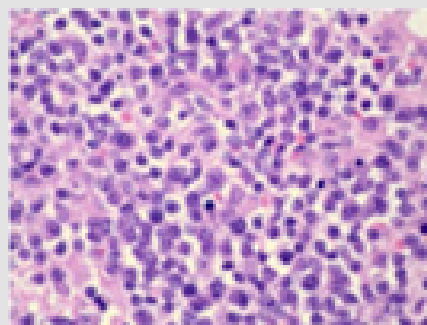
The infection is associated with elevated titres of viral capsid antigen (VCA) immunoglobulin G (IgG) and early antigen (EA) immunoglobulin G (IgG). However, accompanying malignant transformation, autoimmune disease or immunodeficiency is absent [1,2]. Systemic

EBV+ T cell lymphoma of childhood occurs within children and young adults. A specific gender predilection is absent. The condition is prevalent in Asians and manifests as a version of chronic active Epstein Barr viral infection wherein progression into Epstein Barr virus induced T cell lymphoproliferative disorder is uncommonly discerned [1,2]. In contrast, Japanese subjects with chronic active Epstein Barr viral infection manifest with pyrexia, hepatosplenomegaly, extensive lymphadenopathy, pancytopenia, enhanced viral copy numbers circulating within peripheral blood T cells or NK cells and a monoclonal cellular proliferation, wherein the severe condition commonly evolves into a malignant disorder. The disorder is infrequent within Caucasians. Of obscure aetiology, systemic EBV+ T cell lymphoma of childhood may arise in concurrence with primary Epstein Barr viral infection. An intense, definitive racial predisposition is indicative of genetic deficiency within host immune response towards the virus. Infiltrating T lymphocytes demonstrate monoclonal rearrangements within T cell receptor (TCR) genes. Clonal, episomal Epstein Barr virus comprehensively (100%) incriminates neoplastic lymphoid cells configuring the lymphoma [1,2]. Systemic EBV+ T cell lymphoma of childhood may be engendered with cytotoxic CD8+ T lymphocytes or activated CD4+ T cells which are infected with Epstein Barr virus.

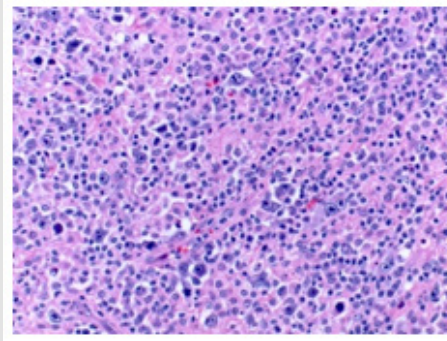
Systemic EBV+ T cell lymphoma of childhood preponderantly arises within spleen, hepatic or pulmonary parenchyma, lymph nodes, bone marrow or diverse cutaneous surfaces [1,2]. Systemic EBV+ T cell lymphoma of childhood incriminates normal subjects demonstrating an acute, primary Epstein Barr viral infection with occurrence of pyrexia, general malaise, possible viral syndrome, hepatosplenomegaly with hepatic failure, pancytopenia, coagulopathy, variable lymphadenopathy, aberrant liver function tests and an extremely fulminant clinical course. Generally, infectious mononucleosis (IM)-like symptoms occurring due to primary Epstein Barr viral (EBV) infection may precede the lymphoma [1,2]. Oral lesions such as aphthous stomatitis, ulcerative gingivitis, vesiculopapular or papulonecrotic mucosal and cutaneous eruptions may ensue. The rapidly progressive condition enunciates emergence of multiple organ failure, hemophagocytic lymphohistiocytosis (HLH) and sepsis

with mortality occurring within few days to weeks. Systemic EBV+T cell lymphoma of childhood is accompanied by complications such as hemophagocytic syndrome, coagulopathies, ulceration of gastrointestinal tract, coronary aneurysm, incrimination of central nervous system, failure of multiple organs and sepsis [1,2]. Upon microscopy, miniature T lymphocytes with minimal or absent cytological atypia appear to infiltrate incriminated sites. Nevertheless, lymphoma may be constituted of atypical lymphoid infiltrates demonstrating pleomorphic, intermediate to enlarged, neoplastic lymphoid cells incorporated with irregular nuclei.

Generally, significant cellular atypia is absent although mitotic activity is frequent [1,2]. Bone marrow, spleen and hepatic parenchyma exhibit histiocytic hyperplasia with significant hemophagocytosis. Spleen and hepatic parenchyma demonstrate hemophagocytosis and mild to preponderant lymphoid infiltration of portal tract and sinusoids. Splenic white pulp appears decimated with prominent sinusoidal and nodular lymphoid infiltrates [1,2]. Hepatic parenchyma delineates portal and sinusoidal infiltration with neoplastic lymphoid cells, cholestasis, steatosis, and focal necrosis. Preliminary morphological features discerned within lymph node exhibit depletion of B cell areas. Expansion of para-cortical or inter-follicular zones occurs due to infiltration by polymorphous population of lymphoid cells comprising of miniature to intermediate lymphoid cells admixed with enlarged, atypical lymphoid cells with irregular nuclei. Disease progression is associated with depletion of lymph nodes. Lymph nodes display preserved architecture, patent vascular sinuses, variable sinus histiocytosis and foci of erythrophagocytosis. Bone marrow exemplifies lymphoid and histiocytic hyperplasia with prominent erythrophagocytosis [1,2] (Table 1). Pulmonary parenchyma enunciates focal necrosis and peribronchial infiltration with tumour cells. Angiocentric foci with angioinvasion may be occasionally discerned. Cutaneous surface exhibits ulceration of superimposed epidermis, neoplastic cellular extension from epidermis into subjacent subcutaneous tissue, focal necrosis, foci of angiocentricity or angioinvasion and peri-appendageal infiltration of neoplastic lymphoid cells [1,2] (Figures 1 & 2).



**Figure 1:** Systemic EBV+T cell lymphoma of childhood demonstrating disseminated small to medium lymphocytes with irregular, convoluted nuclei admixed with enlarged, pleomorphic lymphoid cells [5].



**Figure 2:** Systemic EBV+ T cell lymphoma of childhood delineating miniature to medium T lymphocytes admixed with pleomorphic, enlarged cells simulating Reed Sternberg-like cells [6].

**Table 1:** Epstein Barr virus associated T cell and NK cell lymphoproliferative disorders [2,3].

•EBV+ hemophagocytic lymphohistiocytosis
•Chronic active EBV infection of T cell and NK cell type
~systemic form
~cutaneous form
•Hydroa vacciniforme-like lymphoproliferative disease
•Severe mosquito bite allergy
•Systemic EBV+ T cell lymphoma of childhood
•Aggressive NK cell leukaemia
•Extra-nodal NK/T lymphoma, nasal type
•Primary EBV+ nodal T cell /NK cell lymphoma

Note: EBV: Epstein Barr virus, NK: Natural killer

Systemic EBV+ T cell lymphoma of childhood is immune reactive to CD2, CD3, CD8, as indicative of acute primary Epstein Barr viral infection and CD4 as indicative of severe chronic active Epstein Barr virus (CAEBV) disease. Exceptionally, neoplastic lymphoid cells demonstrate a CD4+ / CD8+ immuno-phenotype. Infiltrating lymphoid cells are preponderantly infected with Epstein Barr virus (EBV+) and are comprised of CD8+ cytotoxic T cells which are immune reactive to CD2, CD3, T cell intracellular antigen1 (TIA1) and granzyme B. Exceptionally, EBV+ infected tumour cells represent with CD4+/CD8+ immuno-phenotype [3,4]. Systemic EBV+ T cell lymphoma of childhood is immune non-reactive to CD56. Tumour cells appear immune non-reactive to latent membrane protein 1 (LMP1) and Epstein Barr virus nuclear antigen 2(EBNA2). Occurrence of intracellular Epstein Barr virus (EBV) may be confirmed with in situ hybridization (ISH) [3,4]. Upon in situ hybridization, tumour cells appear immune reactive to T cell intracellular antigen 1(TIA1), granzyme B and Epstein Barr virus encoded small RNAs (EBERs). Systemic EBV+ T cell lymphoma of childhood demonstrates monoclonal rearrangement of T cell receptor gene [3,4]. The clonal, episomal configuration of Epstein Barr

virus type A, wild type or 30bp deleted product of latent membrane protein 1 (LMP1) is comprehensively (100%) encountered within the lymphoma. The lymphoma is devoid of consistent chromosomal anomalies although chromosomal 6q deletion is frequently encountered [3,4]. Systemic EBV+ T cell lymphoma of childhood is accompanied by pancytopenia, aberrant liver function tests and abnormal serological assay of Epstein Barr virus with minimal to absent anti-viral capsid antigen (anti-VCA) immunoglobulin M(IgM) antibodies.

Radiographic examination demonstrates interstitial pneumonia confined to pulmonary parenchyma, calcification of basal ganglia or coronary aneurysms [3,4]. Systemic EBV+ T cell lymphoma of childhood is devoid of standardized therapeutic guidelines. Lymphoma is resistant to conventional chemotherapy. However, hematopoietic stem cell transplant may be beneficially employed. As the lymphoma predominantly demonstrates a fulminant clinical course, mortality ensues within days to weeks. However, subjects may delineate a sub-acute clinical course extending to several months or a year [3-5].

**References**

1. Nagahama J, Nishikawa T, Tasaki T, Yuki Yasudome, Tatsuro Nakamura, et al. (2022) Systemic Epstein-Barr virus-positive T-cell lymphoma of childhood treated with the ICE regimen and allogeneic hematopoietic stem-cell transplantation. *Pediatr Blood Cancer* 70(3): e30041.
2. Wang Z, Kimura S, Iwasaki H, Ken Takase, Yumi Oshiro, et al. (2021) Clinicopathological findings of systemic Epstein-Barr virus-positive T-lymphoproliferative diseases in younger and older adults. *Diagn Pathol* 16(1): 48.
3. Robbins DJ, Ranheim EA, Kallan JE (2022) Unsuspected systemic Epstein-Barr virus-positive T-cell lymphoma of childhood diagnosed at autopsy in a potential homicide case. *J Pathol Transl Med* 57(2): 123-127.
4. Wu Q, Ren F, Elston DM (2019) Systemic Epstein-Barr virus-positive T-cell lymphoma of childhood. *Cutis* 104(5): 297-300.
5. Valentina Tabanelli, Claudio Agostinelli, Elena Sabattini, Anna Gazzola, Francesco Bacci, et al. (2011) Systemic Epstein-Barr-virus-positive T cell lymphoproliferative childhood disease in a 22-year-old Caucasian man: A case report and review of the literature. 5: 218.

ISSN: 2574-1241

DOI: [10.26717/BJSTR.2023.51.008152](https://doi.org/10.26717/BJSTR.2023.51.008152)

Anubha Bajaj, Biomed J Sci & Tech Res



This work is licensed under Creative Commons Attribution 4.0 License

Submission Link: <https://biomedres.us/submit-manuscript.php>



#### Assets of Publishing with us

- Global archiving of articles
- Immediate, unrestricted online access
- Rigorous Peer Review Process
- Authors Retain Copyrights
- Unique DOI for all articles

<https://biomedres.us/>