

# Meigs Syndrome with Highly Elevated CA125

Shiomi Ushida<sup>1</sup>, Satoshi Ichigo<sup>1</sup>, Hiroshi Takagi<sup>1</sup>, Kazutoshi Matsunami<sup>1</sup>, Yuji Ito<sup>2</sup> and Atsushi Imai<sup>1\*</sup>



<sup>1</sup>Department of Obstetrics and Gynecology, Matsunami General Hospital, Japan

<sup>2</sup>Department of Obstetrics and Gynecology, Ena Municipal Hospital, Japan

\*Corresponding author: Atsushi Imai, Department of Obstetrics and Gynecology, Matsunami General Hospital, 185-1 Dendai, Kasamatsu, Gifu 501-6062, Japan

## ARTICLE INFO

**Received:** 📅 September 05, 2022

**Published:** 📅 September 15, 2022

**Citation:** Shiomi Ushida, Satoshi Ichigo, Hiroshi Takagi, Kazutoshi Matsunami, Yuji Ito, et al. Meigs Syndrome with Highly Elevated CA125. Biomed J Sci & Tech Res 46(2)-2022. BJSTR. MS.ID.007313.

## ABSTRACT

Meigs syndrome is an unusual condition consisting of benign solid ovarian tumors accompanied by ascites and/or pleural effusion. Usually Meigs syndrome does not result in serum CA125 elevation. The elevated CA125 level (>1000 U/ml) occurs more frequently in those with larger size tumor (>10cm) of Meigs syndrome. It has a clinical picture closely resembled to malignant ovarian cancer. Because diagnosis can only be made after pathological examination, surgery is an excellent tool for treatment with subsequent resolution of the ascites and hydrothorax.

## Introduction

Meigs syndrome is an unusual condition and first classified as a triad of benign solid ovarian tumors (fibroma, fibrothecoma, granulosa cell tumor, or Brenner tumor) with both ascites and pleural effusion [1,2]. The characteristic feature of the syndrome is complete disappearance of ascites and pleural effusion following

the surgical removal of the tumor. This rare clinical form occurs with a low incidence rate, with only 1% of ovarian solid tumors present as Meigs syndrome [1,2]. Meigs syndrome with serum CA125 elevation is not frequently encountered in clinical practice. We aim to understand the unusual manifestations of Meigs syndrome combined with an elevated CA125 level (Table 1).

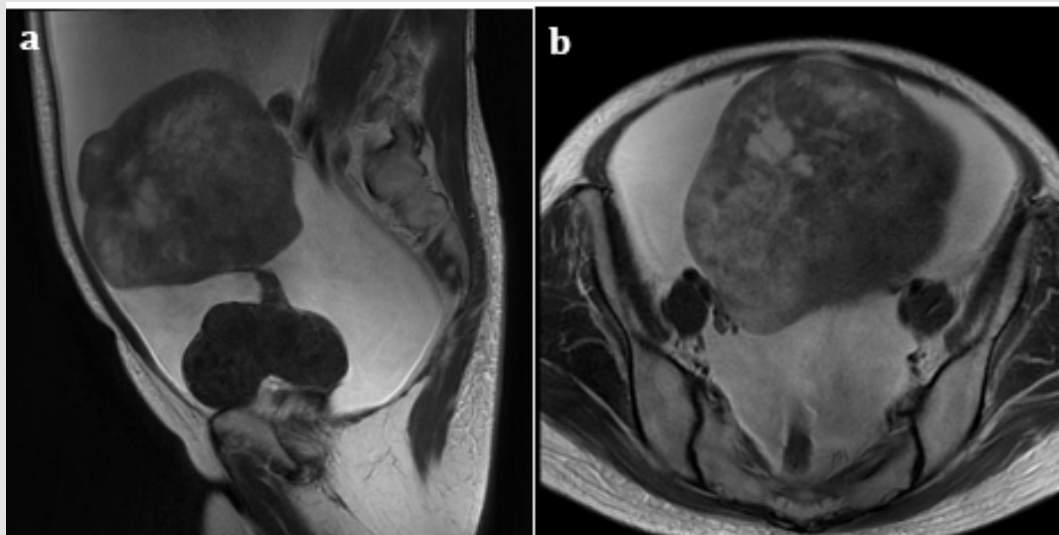
**Table 1:** Reported cases of Meigs' syndrome with elevated serum CA125.

Author	Patient' age	Histopathology	Tumor diameter, cm	CA125, IU/ml*
Lin, et al. [14]	72	Fibroma	12	>7000
Walker, et al. [17]	52	Cellular fibroma	17	>5000
Danilos J, et al. [18]	50	Fibrothecoma	10	2310
Palmieri, et al. [19]	64	Fibroma	26	2124
Loué, et al. [20]	35	Fibrothecoma	40	1835
Morán-Mendoza, et al. [21]	46	Fibroma	25	1808
Siddiqui and Toub [22]	73	Cellular fibroma	15	
Patsner [23]	72	Fibroma	13	1200
Benjapibal, et al. [9]	56	Fibroma	13	1064

Navarro-Esteva, et al. [24]	59	Fibroma	21	>1000
Current case	49	Fibroma	14	3969

Note: \*normal being <35 U/ml.

### Characteristics of CA125



**Figure 1:** A case of Meigs syndrome with highly elevated CA125. A 49-year-old woman presented with ascites and pleural effusion. MRI sagittal (a) and horizontal (b) Images of pelvis (T2-weighted) showed a large heterogenous solid mass originating from the left ovary measuring 11x14x11 cm and huge amount of ascites. Serum CA125 was found to be elevated at 3969 U/ml. The patient was submitted to an exploratory laparotomy which detected 10200 ml of serous ascites. She underwent a total abdominal hysterectomy and bilateral salpingo-oophorectomy. Pathology revealed ovarian fibromas. After removal of pelvic tumor the symptoms completely relieved, and CA125 level on the 14th postoperative day was 22U/ml.

CA125 is a large mucinous membrane glycoprotein and recognized by a monoclonal antibody OC-125. It is produced in the normal and abnormal tissues of Müllerian origin including amniotic membrane and embryonic coelomic epithelium [3]. This antigen can also appear in many adult tissues such as the fallopian tubes epithelium, endometrium, cervix, and ovaries [4]. It is also found in mesothelial cells of peritoneum, pericardium and pleura. Therefore, some normal body tissues may express a constant low level of circulatory or serum CA125, whereas high levels of CA125 are exceptionally rarely observed. This marker is found to be elevated during menstruation or pregnancy and in some benign conditions including endometriosis, peritonitis or cirrhosis, particularly with ascites [5,6]: these cause peritoneum irritation and release of inflammatory mediators. It is also increase in vascular invasion, inflammation and tissue destruction associated with malignant disease [7].

### Cases with Severely Elevated CA125

Ovarian fibroma/fibrothecoma originates from the sex-cord stromal and belongs to the subgroup of granulosa-theca cell tumors and the thecoma-fibroma group, according to the WHO classification. Its incidence in all ovarian tumors is estimated to be less than 5% [8]. This tumor often exhibits benign behavior and a

good prognosis. The most common manifestation is a unilateral, asymptomatic pelvic mass. Ovarian fibroma/fibrothecoma with elevated serum CA125 level rarely occurs in clinical practice, and is mentioned in only 10-20% of Meigs' syndrome patients in the published literature [9,10,11]. A literature review using PubMed yielded 11 cases with Meigs syndrome showing elevated CA125 level (>1000 U/ml) (Table 1). Mean tumor size was 18.7 cm. All patients were released from the clinical symptoms following surgical removal. Meigs syndrome is most common in postmenopausal women with an average age of about 50 years [12,13]. It is extremely rare in women under the age of 30. Several analyses have postulated that high CA125 level may be age-related (most of the cases were in their 70s) [11], it was distributed from 30s to 70s (Table 1). includes one patient with ovarian fibroma and elevated serum CA125 (3969 U/ml). Details are given in (Figure 1).

### Possible Explanations of CA125 Elevation

The source of serum CA125 in ovarian fibroma/fibrothecoma has not yet been elucidated, but mesothelial expression of CA125, rather than expression by the fibroma/fibrothecoma, may result in the elevation [14,15]. In an immunohistochemical staining study by (Shen, et al. [13]), the CA125 expression is negative in all fibroma/fibrothecoma tissues examined, but positive in all epithelial ovarian

cancer tissues. CA125 staining is localized in the cytomembrane. The elevated serum CA125 levels in ovarian fibroma/fibrothecoma are nontumor originated and occur more frequently in patients with larger-sized tumor of Meigs' syndrome. The mechanism consists of previous findings that the peritoneal mesothelial cells might play a critical role in the mechanism of developing elevated serum CA125 [15,16].

## Conclusion

Meigs syndrome presenting with an elevated CA125 is a rare clinical entity [17-24]. This condition mimics an ovarian malignancy, but Meigs syndrome should be considered in the differential diagnosis. It has a clinical picture closely resembled to malignant ovarian cancer. Because diagnosis can only be made after pathological examination, surgery is an excellent tool for treatment with subsequent resolution of the ascites and hydrothorax.

## Conflict of Interest

The authors declare that they have no conflict of interest.

## References

- Saha S, Robertson M Australas J (2012) Meigs' and Pseudo-Meigs' syndrome. *Ultrasound Med* 15(1): 29-31.
- Meigs JV (1954) Pelvic tumors other than fibromas of the ovary with ascites and hydrothorax. *Obstet Gynecol* 3(5): 471-486.
- Bast RC Jr, Feeney M, Lazarus H, Nadler LM, Knapp RC, et al. (1981) Reactivity of a monoclonal antibody with human ovarian carcinoma. *J Clin Invest* 68(5): 1331-1337.
- Kabawat SE, Bast RC Jr, Bhan AK, Welch WR, Knapp RC, et al. (1983) Tissue distribution of a coelomic-epithelium-related antigen recognized by the monoclonal antibody OC125. *Int J Gynecol Pathol* 2(3): 275-285.
- Jacobs I, Bast RC Jr (1989) The CA 125 tumour-associated antigen: a review of the literature. *Hum Reprod* 4(1): 1-12.
- Kudlacek S, Schieder K, Kölbl H, Neunteufel W, Nowotny C, et al. (1989) Use of CA 125 monoclonal antibody to monitor patients with ovarian cancer. *Gynecol Oncol* 35(3): 323-329.
- O Connell GJ, Ryan E, Murphy KJ, Prefontaine M (1987) Predictive value of CA 125 for ovarian carcinoma in patients presenting with pelvic masses. *Obstet Gynecol* 70(6): 930-932.
- Brun JL (2007) Demons syndrome revisited: a review of the literature. *Gynecol Oncol* 105(3): 796-800.
- Benjapibal M, Sangkarat S, Laiwejpithaya S, Viriyapak B, Chaopotong P, et al. (2009) Meigs' Syndrome with Elevated Serum CA125: Case Report and Review of the Literature. *Case Rep Oncol* 2(1): 61-66.
- Chen H, Liu Y, Shen LF, Jiang MJ, Yang ZF, et al. (2016) Ovarian thecoma-fibroma groups: clinical and sonographic features with pathological comparison. *J Ovarian Res* 9(1): 81.
- Chechia A, Attia L, Temime RB, Makhlof T, Koubaa A, et al. (2008) Incidence, clinical analysis, and management of ovarian fibromas and fibrothecomas. *Am J Obstet Gynecol* 199(5): 473.e1-4.
- Shiau CS, Chang MY, Hsieh CC, Hsieh TT, Chiang CH, et al. (2005) Meigs' syndrome in a young woman with a normal serum CA-125 level. *Chang Gung Med J* 28(8): 587-591.
- Shen Y, Liang Y, Cheng X, Lu W, Xie X, et al. (2018) Ovarian fibroma/fibrothecoma with elevated serum CA125 level: A cohort of 66 cases. *Medicine (Baltimore)* 97(34): e11926.
- Lin JY, Angel C, Sickel JZ (1992) Meigs syndrome with elevated serum CA 125. *Obstet Gynecol* 80: 563-566.
- Timmerman D, Moerman P, Vergote I (1995) Meigs' syndrome with elevated serum CA 125 levels: two case reports and review of the literature. *Gynecol Oncol* 59(3): 405-408.
- Yazdani S, Alijanpoor A, Sharbatdaran M, Bouzari Z, Abedisamakoosh M, et al. (2014) Meigs' syndrome with elevated serum CA125 in a case of ovarian fibroma /thecoma. *Caspian J Intern Med* 5(1): 43-45.
- Walker JL, Manetta A, Mannel RS, Liao SY (1990) Cellular fibroma masquerading as ovarian carcinoma. *Obstet Gynecol* 76: 530-531.
- Danilos J, Michał Kwaśniewski W, Mazurek D, Bednarek W, Kotarski J, et al. (2015) Meigs' syndrome with elevated CA-125 and HE-4: a case of luteinized fibrothecoma. *Prz Menopauzalny* 14(2): 152-154.
- Palmieri A, El Sahwi K, Hicks V (2021) Meigs syndrome presenting with severely elevated CA-125 level. *BMJ Case Rep* 14(3): e238931.
- Loué VA, Gbary E, Kouli S, Akpa B, Kouassi A, et al. (2013) Bilateral Ovarian Fibrothecoma Associated with Ascites, Bilateral Pleural Effusion, and Marked Elevated Serum CA-125. *Case Rep Obstet Gynecol* 2013: 189072.
- Morán Mendoza A, Alvarado Luna G, Calderillo Ruiz G, Serrano Olvera A, López Graniel CM, et al. (2006) Elevated CA125 level associated with Meigs' syndrome: case report and review of the literature. *Int J Gynecol Cancer* 16(Suppl 1): 315-318.
- Siddiqui M, Toub DB (1995) Cellular fibroma of the ovary with Meigs' syndrome and elevated CA-125. A case report. *J Reprod Med* 40(11): 817-819.
- Patsner B (2000) Meigs syndrome and "false positive" preoperative serum CA-125 levels: analysis of ten cases. *Eur J Gynaecol Oncol* 21(4): 362-363.
- Navarro Esteva J, Laseca Modrago M, Arencibia Sánchez O (2020) Two patients with Meigs' syndrome and elevated serum CA-125: a case report. *Cureus* 12(6): e8927.

ISSN: 2574-1241

DOI: 10.26717/BJSTR.2022.46.007313

Atsushi Imai. Biomed J Sci & Tech Res



This work is licensed under Creative Commons Attribution 4.0 License

Submission Link: <https://biomedres.us/submit-manuscript.php>



#### Assets of Publishing with us

- Global archiving of articles
- Immediate, unrestricted online access
- Rigorous Peer Review Process
- Authors Retain Copyrights
- Unique DOI for all articles

<https://biomedres.us/>