

The Trailing Fecundation Epithelioid Trophoblastic Tumour

Anubha Bajaj*

Consultant Histopathologist, A. B. Diagnostics, India

*Corresponding author: Anubha Bajaj, Consultant Histopathologist, A. B. Diagnostics, A-1 Ring Road Rajouri Garden, New Delhi 110027, India



ARTICLE INFO

Received: 📅 June 15, 2022

Published: 📅 June 27, 2022

Citation: Anubha Bajaj. The Trailing Fecundation Epithelioid Trophoblastic Tumour. Biomed J Sci & Tech Res 44(5)-2022. BJSTR. MS.ID.007107.

ABSTRACT

Abbreviations: WHO: World Health Organization; ETT: Epithelioid Trophoblastic Tumour; GTN: Gestational Trophoblastic Neoplasia; HCG: Human Chorionic Gonadotropin; POCs: Products of Conception; CK: Cytokeratin Cocktail; EMA: Epithelial Membrane Antigen; HLA-G: Human Leucocyte Antigen G; HPL: Human Placental Lactogen; HCG: Human Chorionic Gonadotrophin; FIGO: International Federation of Obstetrics and Gynaecology; AUB: Abnormal Uterine Bleeding

Preface

The World Health Organization (WHO) classifies Epithelioid Trophoblastic Tumour (ETT) as a category of Gestational Trophoblastic Neoplasia (GTN). Initially scripted by Shih and Kurman in 1998, the exceptional epithelioid trophoblastic tumour emerges as a derivative of neoplastic, chorionic- type, intermediate trophoblastic tissue and is associated with a variable clinical representation [1]. Epithelioid trophoblastic tumour may frequently coexist with placental-site trophoblastic tumour and the entities necessitate appropriate segregation. Nevertheless, a comprehensive, universally accepted protocol of tumour discernment, appropriate therapeutic regimen and duration of therapy for epithelioid trophoblastic tumour remains obscure.

Disease Characteristics

Epithelioid trophoblastic tumour commonly occurs within the reproductive age group and is usually discerned following a gestational event such as a full-term delivery, molar pregnancy or spontaneous abortion. Tumefaction is exceptionally delineated within postmenopausal women [2,3]. Epithelioid trophoblastic

tumour appears to be associated with a preceding gestational trophoblastic neoplasm, preceding normal pregnancy or preceding spontaneous abortion [2,3]. Epithelioid trophoblastic tumour follows antecedent pregnancy by several months or years. Generally, the neoplasm may follow a previous gestational event beyond > 6 years [2,3]. Serum beta Human Chorionic Gonadotropin (β -HCG) levels appear elevated [2,3]. Epithelioid trophoblastic tumour configures up to 2% of gestational trophoblastic neoplasia (GTN) and is associated with proportionate mortality of nearly 24%. Incidence of epithelioid trophoblastic tumour following a term pregnancy is nearly 1 in 150,000 pregnancies. The neoplasm exhibits pertinent ethnic variation [2,3]. Commonly, tumefaction may be situated within the uterine fundus, lower uterine segment or endo-cervix. Infrequently, pulmonary parenchyma or abdominal wall exhibit the lesion in the absence of a uterine neoplasm. Non metastatic neoplasms confined to the uterus are associated with comprehensive (~100%) disease- associated survival although metastatic tumours demonstrate around 60% proportionate survival [2,3].

Clinical Elucidation

The neoplasm is commonly discerned upon locations such as uterus or lower uterine segment, cervix or pulmonary parenchyma. Sites such as vagina, broad ligament, fallopian tubes or associated pelvic organs are infrequently implicated [4,5]. The gradually progressive neoplasm remains confined within the uterus for an extended duration. Thus, vaginal bleeding or amenorrhea is a commonly discerned clinical symptom [4,5]. Incriminated subjects depict irregular, variable vaginal bleeding, Abnormal Uterine Bleeding (AUB) or mild vaginal discharge. Preceding gestational event followed by abnormal uterine bleeding may indicate the occurrence of gestational trophoblastic neoplasia as epithelioid trophoblastic tumour [4,5]. The neoplasm may manifest as a nodule confined to a Caesarean scar or follow a spontaneous abortion with retained Products of Conception (POCs) [4,5]. Generally, the lower uterine segment exhibits a painful tumefaction of variable magnitude and vaginal bleeding along with mildly elevated serum beta Human Chorionic Gonadotropin (β -HCG) levels [4,5]. Majority of neoplasms are devoid of a Y chromosome complement [4,5].

Histological Elucidation

Macroscopically, discrete tumour nodules or a cystic or haemorrhagic tumour mass exhibits deep-seated infiltration within circumscribing soft tissue. Cut surface is whitish, tan or brown and depicts focal haemorrhage and tumour-induced necrosis. Focal ulceration and configuration of a fistula is frequently observed [6,7]. Grossly, a well-defined, pearly white, friable tumefaction with a fascicular external surface and magnitude of up to 5 centimeters appears to invade the uterine serosa and incriminates in excess of > 50% of myometrium. Usually, the neoplasm emerges as a solid, well circumscribed lesion confined to the cervix or as an extra-uterine, localized tumefaction. Besides, the neoplasm may manifest as a discrete, solitary, nodule with a well circumscribed perimeter [6,7]. Cut surface is solid, tan or brown with focal haemorrhage and necrosis. Frequently, the neoplasm configures nodules or tumour masses and depicts an expansive growth pattern [6,7]. Upon microscopy, tumefaction is composed of solid cellular zones, elongated articulations and tumour cell nests. The well-defined, nested growth pattern is configured of miniature tumour cells with minimal nuclear pleomorphism and lack of intercellular bridges. A “pushing” tumour perimeter is exemplified by the neoplasm [6,7]. The nodular, well circumscribed neoplasm exhibits focal, peripheral tumour infiltration. Mononuclear, uniform tumour cells are configured in nests and cords. Tumour cell nests are admixed with an eosinophilic, fibrillary, hyaline-like substance composed of type IV collagen along with onco-foetal and adult subtypes of fibronectin [6,7]. Cells of chorionic-type, intermediate trophoblastic tissue exhibit moderate, eosinophilic to clear cytoplasm imbued

with glycogen, spherical nuclei, miniature, distinctive nucleoli and distinct cellular membranes. Tumour calcification is frequent [6,7]. Circumscribing stromal cells appear decidua-like. Exceptionally, focal regions resembling placental-site nodule, placental-site trophoblastic tumour or choriocarcinoma can be discerned [6,7]. The neoplasm can simulate mature stratified squamous epithelium and appears to re-epithelialize endometrial surface or endocervix. Fragments of endocervical tissue may be admixed with clusters of intermediate trophoblastic cells [6,7]. Mean tumour mitotic count appears at an estimated 2 per 10 high power fields although up to 20 mitosis per 10 high power fields may be discerned. Atypical mitotic figures can be delineated. Tumefaction enunciates extensive or “geographic” necrosis [6,7]. Tumour is composed of intermediate trophoblastic cells imbued with abundant eosinophilic cytoplasm and vesicular nuclei. Tumour cell aggregates are surrounded by a fibrous tissue stroma whereas tumour cells may circumscribe and replace walls of medium-sized vascular articulations and spaces [6,7]. Uterine serosa abutting the neoplasm may depict zonal rupture with tumour cell infiltration and focal necrosis. Soft tissue perimeter may be devoid of discernible tumour cell infiltration. Adjacent pelvic lymph nodes are preserved and lack tumour metastases [6,7].

Immunohistochemistry

Tumour cells are intensely, diffusely immune reactive to Cytokeratin Cocktail (CK) AE1/AE3, cytokeratin 18, Cyclin E, Cyclin D1, CD10, Epithelial Membrane Antigen (EMA), inhibin- α , E-cadherin, prolyl 4-hydroxylase, Human Leucocyte Antigen G(HLA-G), hydroxy-delta-5-steroid dehydrogenase 3 beta and steroid delta-isomerase 1 (HSD3B1), GATA3 and p63. Focal immune reactivity to Human Placental Lactogen (HPL), Human Chorionic Gonadotrophin (HCG) and CD146 (Mel-CAM) is observed [8,9]. Ki-67 nuclear labelling index exceeds > 10%. The neoplasm may display immune staining with PD-L1, thus corroborating beneficial therapeutic outcomes with employment of immune checkpoint inhibitors [8,9]. Tumour cells are immune non-reactive to smooth muscle actin (SMA), desmin and CD117 [8,9] (Figures 1-8) [10-16].

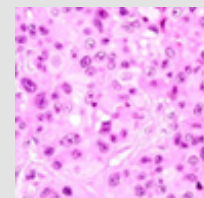


Figure 1: Epithelioid trophoblastic tumour exemplifying nests and cords of intermediate trophoblastic cells with abundant, eosinophilic cytoplasm and vesicular nuclei [10].

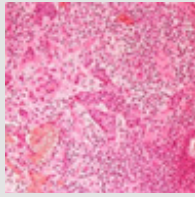


Figure 2: Epithelioid trophoblastic tumour exhibiting nests and cords of intermediate trophoblastic cells with eosinophilic cytoplasm and vesicular nuclei and a circumscribing stroma with tumour cells replacing vascular articulations [10].

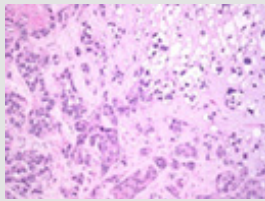


Figure 3: Epithelioid trophoblastic tumour enunciating cords and aggregates of intermediate trophoblastic cells admixed with foci of necrosis [11].

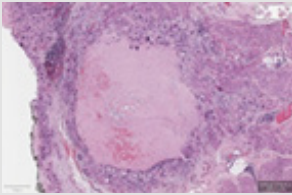


Figure 4: Epithelioid trophoblastic tumour depicting aggregates of intermediate trophoblastic cells surrounding zones of geographic necrosis [12].

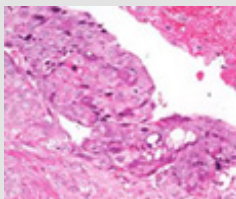


Figure 5: Epithelioid trophoblastic tumour delineating a layering of intermediate trophoblastic cells with eosinophilic cytoplasm and focal necrosis [13].

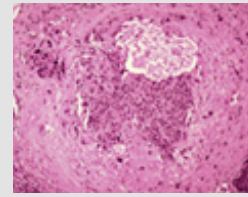


Figure 5: Epithelioid trophoblastic tumour demonstrating intermediate trophoblastic cells invading vascular elastic tissue and circumscribing vascular lumen [14].

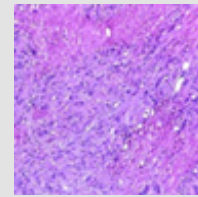


Figure 7: Epithelioid trophoblastic tumour displaying strands of intermediate trophoblastic cells admixed with enlarged foci of geographic necrosis [15].

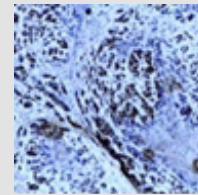


Figure 8: Epithelioid trophoblastic tumour with intermediate trophoblastic cells immune reactive to p63 [16].

Differential Diagnosis

Epithelioid trophoblastic tumour requires a segregation from conditions such as

a) A typical placental site nodule which is discovered incidentally and characteristically displays moderate to severe cytological atypia of the trophoblastic tissue. A borderline Ki-67 nuclear labelling index of up to 10% is observed [17,18].

b) Keratinizing squamous cell carcinoma of the cervix is composed of tumour cells which configure and infiltrate surrounding stroma as irregular, anastomosing tumour cell nests

or singular cells. Enveloping stroma can be desmoplastic or invaded by inflammatory cells. Foci of stromal dehiscence or desmoplastic reaction can be observed [17,18]. Superficial stromal invasion or lymphoid and vascular invasion may be delineated. Tumour grading is contingent to features such as nuclear pleomorphism, nucleolar magnitude, mitotic activity and tumour cell necrosis. Keratin pearls, abundant keratohyaline granules and intercellular bridges may be exemplified. Tumour cells depict enlarged, hyperchromatic nuclei, coarse chromatin and inconspicuous nucleoli. The neoplasm is immune reactive to cytokeratin 5, cytokeratin 6 and p16. Tumefaction is immune non reactive to cytokeratin 18 [17,18].

c) Placental site nodule is a lesion discovered incidentally upon microscopy. The minimally cellular lesion exhibits trophoblastic cells imbued with bland nuclei. Extensive hyalinization and an absence of calcification or necrosis is observed. Mitotic activity is minimal and a decimated Ki-67 nuclear labelling index of below < 8% is delineated [17,18].

d) Placental-site trophoblastic tumour exhibits an infiltrative pattern of tumour expansion. Disseminated, multinucleated, intermediate trophoblastic cells accumulated upon the implantation site are common. Frequently, tumour cells appear aggregated into confluent sheets [17,18]. Peripheral neoplastic fragments exhibit singularly disseminated cells, cords or nests of trophoblastic cells. Characteristically, tumour cells segregate individual fibres or group of muscle fibres and infiltrate the myometrium. Vascular invasion is common wherein tumour cells infiltrate and replace walls of myometrial vascular articulations. Tumour cells are incorporated with an abundant amphophilic, eosinophilic or clear cytoplasm, pleomorphic, enlarged, convoluted or hyperchromatic nuclei associated with significant nuclear atypia. Majority of neoplasms depict a minimal mitotic count. Focal calcification or necrosis is absent. The neoplasm is diffusely immune reactive to Mel-CAM and Human Placental Lactogen (HPL). Ki-67 nuclear labelling index is elevated to up to 30% [17,18].

Investigative Assay

Upon ultrasonography, a tumefaction of variable magnitude may be discerned within the lower uterine segment or region of Caesarean scar. Sonography depicts a sharply defined tumefaction along with a hypoechoic halo situated upon the site of a preceding surgical procedure [19,20]. Upon ultrasonography, epithelioid trophoblastic tumour may manifest as a neoplasm with a well circumscribed perimeter and a hypo-echogenic halo [19,20]. Intraoperative inspection may depict a scar associated dehiscence situated upon the site of preceding surgery. Adjoining viscera may be uninvolved [19,20]. Computerized tomography of the thoracic, abdominal and pelvic cavity may exhibit tumour metastasis [19,20].

Colour Doppler may exemplify a specific “peripheral” pattern of vascular outflow. Colour Doppler of tumefaction associated with dehiscence of surgical scar appears devoid of central or peripheral vascular perfusion. Serum beta Human Chorionic Gonadotropin (B-HCG) levels are elevated whereas Human Placental Lactogen (HPL) values appear normal and are non indicative of disease activity or prognostic outcomes [19,20].

Therapeutic Options

Comprehensive surgical excision of the neoplasm is recommended and an optimal therapeutic strategy. Total abdominal hysterectomy along with or the absence of bilateral salpingo-oophorectomy or adnexal eradication is contemplated as a cogent treatment modality for epithelioid trophoblastic tumour. Alternatively, an exploratory laparotomy may be performed [19,20]. A haematoma may accompany the neoplasm confined to isthmus or diverse uterine segments. Morphologically, circumscribing pelvic viscera appear intact and uninvolved. Reconstruction of the uterus may be required [19,20]. Adjuvant chemotherapy is usually unnecessary and the neoplasm appears resistant to chemotherapy. Stage I disease can be appropriately managed with total abdominal hysterectomy [19,20]. Prognostic factors indicating unfavourable outcomes are designated as

- a)** Duration from antecedent pregnancy exceeding > 48 months
- b)** Elevated mitotic count exceeding > 6 mitosis per 10 high power fields
- c)** Cellular and nuclear atypia
- d)** Vascular invasion
- e)** Myometrial invasion beyond inner one third of uterine myometrium
- f)** Diffuse, multifocal uterine disease
- g)** Stage III or stage IV disease as per International Federation of Obstetrics and Gynaecology (FIGO) anatomical staging. Pertinent staging is a significant prognostic factor [19,20]. Tumefaction following antecedent pregnancy beyond > 48 months in the absence of adverse factors can be subjected to surgical procedures as total abdominal hysterectomy with bilateral salpingectomy wherein adjuvant chemotherapy remains unnecessary, especially in individuals wishing to preserve fertility. Oophorectomy may be circumvented in macroscopically unremarkable ovaries [19,20]. Neoplasms associated with metastasis are suitably managed with surgical resection and adjuvant chemotherapy [19,20]. A combination of complex surgical manoeuvres along with adjuvant chemotherapy is recommended in females with elevated serum

beta human chorionic gonadotropin (β -HCG) levels and metastatic disease. Commonly, an antecedent gestational event exceeding > 48 months and advanced disease stage are cogent indicators of an inferior prognostic outcome [19,20].

References

- Shih IM, Kurman RJ (1998) Epithelioid trophoblastic tumour a neoplasm distinct from choriocarcinoma and placental site trophoblastic tumor simulating carcinoma. *Am J Surg Pathol* 22(11): 1393-1403.
- Aničić R, Rakić A, Aleksandar Ristić, Elena Đaković, Lazar Nejković, et al. (2021) A Rare Case of Epithelioid Trophoblastic Tumour Presenting as Hematoma of a Caesarean Scar in the Lower Uterine Segment. *Medicina (Kaunas)* 58(1): 34.
- Yang J, Zong L, Xirun Wan, Fengzhi Feng, Yang Xiang, et al. (2019) Epithelioid Trophoblastic Tumours: Treatments, Outcomes, and Potential Therapeutic Targets. *J Cancer* 10(1): 11-19.
- Gadducci A, Carinelli S, Maria Elena Guerrieri, Giovanni Damiano Aletti (2019) Placental Site Trophoblastic Tumour and Epithelioid Trophoblastic Tumour: Clinical and Pathological Features, Prognostic Variables and Treatment Strategy. *Gynecol Oncol* 153: 684-693.
- Zhang X, Lü W (2013) Epithelioid Trophoblastic Tumour An Outcome-Based Literature Review of 78 Reported Cases. *Int J Gynecol Cancer* 23(7): 1334-1338.
- Black KA, Simone K (2021) Epithelioid Trophoblastic Tumour Presenting as a Caesarean Scar Defect: A Case Report. *Gynecol Oncol Rep* 36: 100715.
- Yang C, Li J, Yuanyuan Zhang, Hanzhen Xiong, Xiujie Sheng, et al. (2020) Epithelioid Trophoblastic Tumour Coexisting with Choriocarcinoma around an Abdominal Wall Caesarean Scar: A Case Report and Review of the Literature. *J Med Case Rep* 14(1): 178.
- Hsiue EHC, Hsu C, Li Hui Tseng, Tzu Pin Lu, Kuan Ting Kuo, et al. (2017) Epithelioid Trophoblastic Tumour Around an Abdominal Caesarean Scar: A Pathologic and Molecular Genetic Analysis. *Int J Gynecol Pathol* 36(6): 562-567.
- Zeng C, Rezaei S, Alexander C Hughes, Cassandra E, Henderson, Juan Liu, et al. (2019) Synchronous Choriocarcinoma and Epithelioid Trophoblastic Tumour Concurring at the Caesarean Scar: A Case Report and Review of the Literature. *Case Rep Obstet Gynecol* (2019): e5093938.
- Image 1 and 2 Courtesy: Pathology outlines.
- Image 3 Courtesy: Webpathology.com
- Image 4 Courtesy: Science direct
- Image 5 Courtesy: Academic oup.com.
- Image 6 Courtesy: Research gate.
- Image 7 and 8 Courtesy: Semantic scholar.
- Frijstein MM, Lok CaR, F Golfier, MC Winter, BW Hancock, et al. (2019) Management and Prognostic Factors of Epithelioid Trophoblastic Tumours: Results from the International Society for the Study of Trophoblastic Diseases Database. *Gynecol Oncol* 152(2): 361-367.
- Aniței MG, Lazăr DE, Cristina Terinte, Radu Iulian, Scripcariu Viorel, et al. (2021) Uterine Epithelioid Trophoblastic Tumour in a 44-Year-Old Woman A Diagnostic Dilemma. *Clin Pract* 11(3): 631-639.
- Hancock BW, Tidy J (2021) Placental Site Trophoblastic Tumour and Epithelioid Trophoblastic Tumour. *Best Pract Res Clin Obstet Gynaecol* 74: 131-148.
- Qin J, Ying W, Xiaoyun Wan, Xing Xie, Weiguo Lu, et al. (2014) A Well-Circumscribed Border with Peripheral Doppler Signal in Sonographic Image Distinguishes Epithelioid Trophoblastic Tumour from Other Gestational Trophoblastic Neoplasms. *PLoS ONE* 9(11): 112618.
- Horowitz NS, Goldstein DP (2017) Placental Site Trophoblastic Tumours and Epithelioid Trophoblastic Tumours: Biology, Natural History, and Treatment Modalities. *Gynecol Oncol* 144: 208-214.

ISSN: 2574-1241

DOI: 10.26717/BJSTR.2022.44.007107

Anubha Bajaj. Biomed J Sci & Tech Res



This work is licensed under Creative Commons Attribution 4.0 License

Submission Link: <https://biomedres.us/submit-manuscript.php>



Assets of Publishing with us

- Global archiving of articles
- Immediate, unrestricted online access
- Rigorous Peer Review Process
- Authors Retain Copyrights
- Unique DOI for all articles

<https://biomedres.us/>