

Garcinia Kola Improves Adrenal and Testicular Tissues Oxidations Via Enhancing Antioxidants Activities in Normal Adult Male Wistar Rats

Osifo CU^{1*} and Iyawe VI^{1,2}

¹Department of Physiology, Faculty of Basic Medical Sciences, College of Medicine, Ambrose Alli University, Ekpoma, Nigeria

²Department of Physiology, School of Basic Medical Sciences, College of Medical Sciences, University of Benin, Benin City-Nigeria

*Corresponding author: Osifo CU, Department of Physiology, Faculty of Basic Medical Sciences, College of Medicine, Ambrose Alli University, Ekpoma, Nigeria



ARTICLE INFO

Received: 📅 July 15, 2020

Published: 📅 July 27, 2020

Citation: Osifo CU, Iyawe VI. *Garcinia Kola* Improves Adrenal and Testicular Tissues Oxidations Via Enhancing Antioxidants Activities in Normal Adult Male Wistar Rats. Biomed J Sci & Tech Res 29(1)-2020. BJSTR. MS.ID.004754.

Keywords: Adrenal Gland; Testis; Oxidative Stress; Antioxidants; *Garcinia Kola*

ABSTRACT

This study investigates the effect of *G. kola* on adrenal and testicular tissues oxidative and antioxidant activities and histology in normal Wistar rats. In a bid to achieve these objectives, 20 adult male Wistar rats were divided into 4 groups after accessing the oral acute toxicity of *G. kola*. Group A served as the control while groups B, C and D were treated on 1000, 1200 and 1400mg/kg of the constituted *G. kola* for 7 days. At the end of treatments, organs weights and histology as well as oxidative and antioxidant activities in tissue homogenates were determined. Using appropriate statistical analysis (ANOVA) the investigated variables were analyzed and results presented as means \pm SEM with $p < 0.05$ considered significant. The results showed that *G. kola* ingestions stimulates adrenal gland and testicular weights, SOD and CAT but inhibits MDA and protein in a dose dependent fashion. Histologically, there was no effect on the adrenal gland but there was dose dependent development of testicular germ cells. This study showed that *G. kola* reduces adrenal and testicular oxidative stress status via stimulation of tissue antioxidants activities.

Introduction

Garcinia kola Heckel (family, Guttiferae); referred to as “bitter kola” or “male kola” because of its bitter taste and the perceived aphrodisiac activity respectively [1], is a plant found in moist forests grows up to a height of 12 meters [2]. It is traditionally regarded as a highly prized item and it is served to visitors in social gatherings as a mark of honour [2]. The plant is regarded as a wonder plant because every part of the plant (bark, leaves, root, and wood) has been found to be of medicinal value [3]. *G. kola* is reported safe when taken with or without other foods and has been documented to increase the absorption of the key ingredients when taking it an hour before or after meals [4]. The medicinal importance of bitter kola has been documented to be based mainly on the phytochemicals of the plant [5].

Phytochemical and biochemical analysis revealed *G. kola* seeds to be a complex mixture of sterols, terpenoids, flavonoids, glycosides,

saponin, tannins, reducing sugar, triterpenoids [6,7], and phenolic compounds including biflavonoids, xanthenes, benzophenones, cycloartenol and triterpenes [3,8,9], Kolaviron [10,11]. In term of percentage, nutritional composition of *G. kola* nut has been documented to be rich in Moisture, dry matter, crude fat, crude protein, ash, crude fiber and total carbohydrates [12-14]. Mineral composition of *G. kola* has been documented to include K, Ca, Mg, Fe, Zn and P as well as a rich source of vitamins [14]. Several studies have documented that plant-derived polyphenolic compounds possess antioxidative properties which can mitigate the damaging effect of ROS and by so doing promote good health in humans [15]. Consequently, a number of evidence-based studies have implicated a strong correlation between the ingestion of fruits, vegetables, and medicinal plant rich in polyphenols with antioxidant potential and the reduced risk of oxidative stress-related disorders [16,17]. Although reactive oxygen species are considered to be unavoidable

by-products of normal aerobic metabolism, they are known to disrupt cellular homeostasis [18].

Chronic stress shifts the balance of hormones to low levels of anabolic hormones and high levels of catabolic hormones [19]. From hormonal point of view, knowing that testosterone is anabolic, and cortisol is catabolic, and that testosterone/cortisol ratio is a great marker for stress [19], it therefore suggest a relationship between the testis and adrenal gland which released these hormones. In fact, steroidogenic cells in the adrenal cortex and testis are reported to arise from a common pool of progenitors in the adrenogonadal primordium, a specialized group of coelomic epithelial cells in the urogenital ridge [20]. According to Heikinheimo et al. [21], the common developmental origin of the adrenal cortex and testis is reflected in overlapping functional profiles for these organs. Thus, the organs may suffer or enjoy together in a condition of exposure to substances or agents. Considering that the adrenal gland and testis are easily exposed to substances ingested by man and animals, and are from common developmental origin couple with the assertion that they may suffer or enjoy together, this study was therefore undertaken to investigate the effect of *G. kola* on the histology of adrenal and testicular tissue as well as the oxidative and antioxidant activities in normal Wistar rats.

Materials and Methods

Adult male Wistar rats (N=32) of comparable weight (180 to 200g) were obtained from the Department of Physiology animal holding unit of the Ambrose Alli University, Ekpoma, Nigeria and were transferred to the site of the experiments. They were housed in plastic cages (measuring 50 x 35 x 25) under standard environmental condition of 12/12hr light/dark cycle and were allowed to acclimatize for two weeks to the laboratory conditions before the experiment and fed ad libitum with rat chow and tap water. *Garcinia kola* (*G. kola*) Heckel Seeds were purchased commercially from a local market in Ekpoma in Edo State, Nigeria. The plant material was authenticated in the herbarium unit of Forestry Research Institute, Ibadan, Nigeria. Thereafter the testas were peeled off the seeds, cut into small sizes and sun dried. This was blended into powder and packed in clean and well covered containers pending when it was used. Oral acute toxicity (LD50) was performed on the grounded seed by Lorke [22] method using 12 rats.

Based on the results of the oral acute toxicity, the remaining 20 rats were divided into 4 groups as followed; group 1 served as untreated control while groups 2, 3 and 4 served as the test groups treated on 1000mg/kg, 1200mg/kg and 1400mg/kg dose of the prepared *G. kola* respectively. These doses of *G. kola* chosen are comparable with previous study by Ahumibe and Braide [23].

Administration of the prepared *G. kola* was as describe by Nwaopara et al. [24]. Briefly, the required grams of crude *G. kola* powder (1000mg/kg, and 1200mg/kg and 1,400mg/kg) were mixed with 20% of normal daily feed (5.0g rat chow) to form paste that was then given to each group of animal. After the rat finished the formed paste, a measured quantity of normal rat chow (80% of 150g) was given to the animal for that day. At the end 7 days treatment the animals were euthanized following cervical decapitation. The testis and adrenal glands were dissected out, devoid of accessory fats and tissues, weighted (using electronic weighing scale) and each dropped in containers containing phosphate buffer (1:10w/v) and 10% formal saline for tissue oxidative stress analysis and histological evaluation respectively.

The tissues (testis and adrenal gland) in phosphate buffer were homogenized and centrifuged at 4000 rpm for 10 minutes to obtain the supernatant which was used for the determination oxidative stress and antioxidant marker. The protein concentration was determined by means of the Biuret method [25] while lipid peroxidation was determined by measuring the thiobarbituric acid reactive substances (TBARS) produced during lipid peroxidation following the method by Varshney and Kale [26]. The level of SOD and Catalase activities were determined by the methods of Misra and Fridovich [27] and Sinha [28] respectively. Following standard histological processing procedures, the tissues in the container containing 10% formal saline were processed and then evaluated under the microscope. The result was analyzed with appropriate statistical analysis (ANOVA) using SPSS 20 and $p < 0.05$ (LSD) was considered statistically significant and then presented as means \pm SEM in charts, tables and microscopic slides.

Results

Table 1 shows the findings of oral acute toxicity study of *G. kola*. Orally, *G. kola* seed was found to be safe at dose as high as 5000 mg/kg body weight. Figure 1 presents the effect of *G. kola* treatments on adrenal gland weight. Although *G. kola* causes a slight increase in adrenal weight, the difference was not significant compared to the control. Table 2 presents the effect of *G. kola* treatments on adrenal gland oxidative and antioxidant markers. There were significant reductions ($p < 0.05$) in adrenal gland tissue MDA and protein levels with 1400mg/kg *G. kola* treatment compared with the control. However, 1200mg/kg and 1400mg/kg *G. kola* treatment resulted in significant increase ($p < 0.05$) in adrenal gland tissue SOD and CAT levels compared to the control. Histological presentations showed (plate 1) normal pattern of cortex zonation showing stainable zona glomerulosa cytoplasm, clear zona fasciculata cytoplasm and zona reticularis acidophilic cytoplasm with normal medulla layers in the 1000, 1200 and 1400mg/kg *G. kola* treated and in the control.

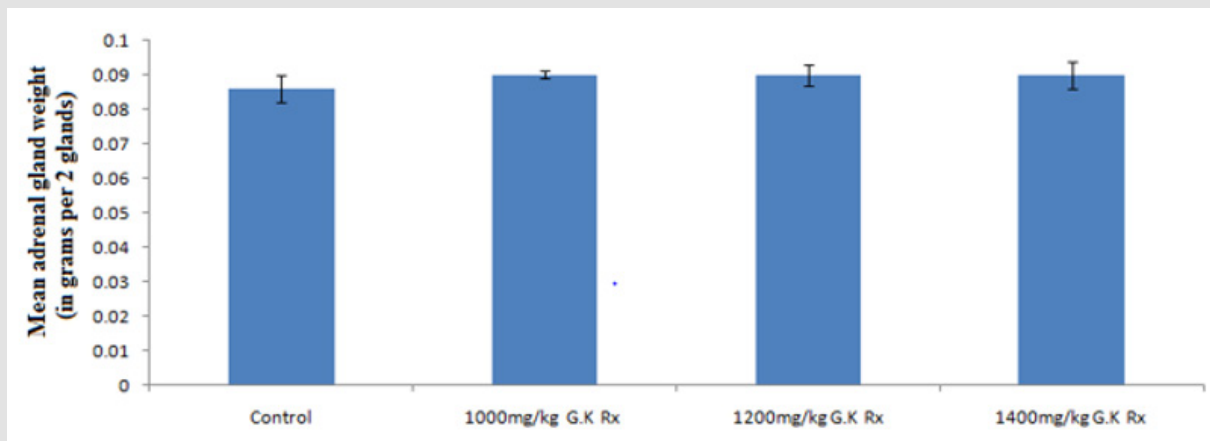


Figure 1: Effect of *G. kola* treatments on adrenal gland weight.

Note: Mean ± SEM of 5 male rats per group.

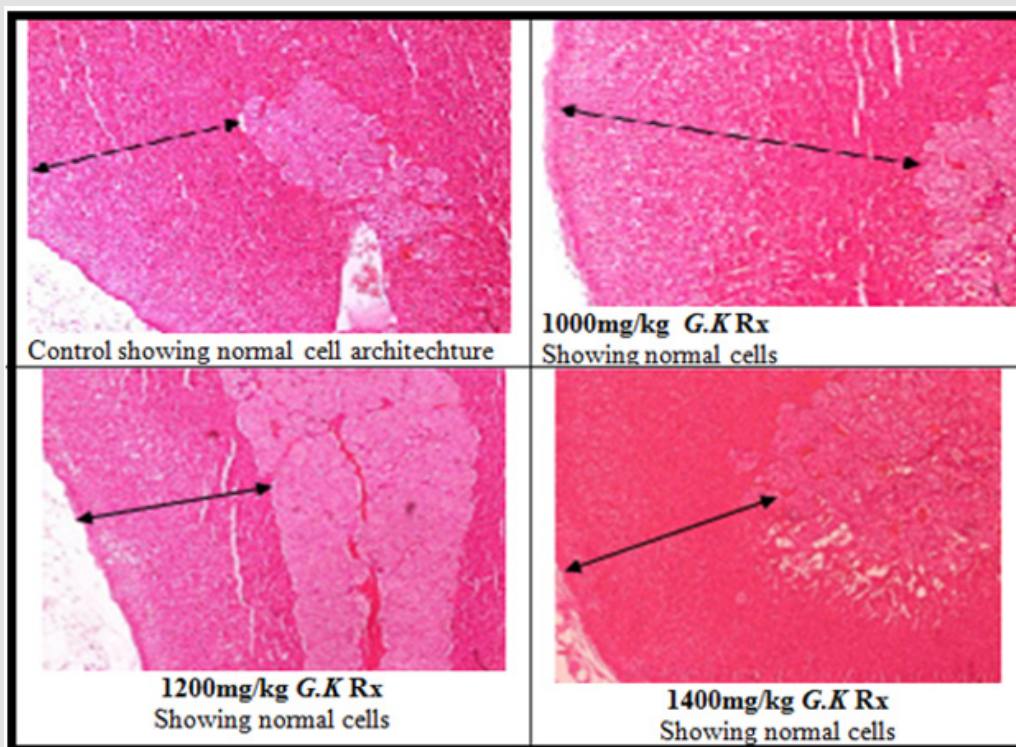


Plate 1: Effect of *G. kola* treatments on adrenal gland tissue histology (Haematoxylin and Eosin stained x100).

Table 1: Oral acute toxicity study of *G. kola*.

Groups	Number of rat	Dose of <i>G. kola</i> seed (mg/kg body weight)	Mortality	Percentage mortality
Phase 1				
A1	3	10	0	0%
B1	3	100	0	0%
C1	3	1000	0	0%
Phase 2				
A2	1	1500	0	0%
B2	1	3000	0	0%
C2	1	5000	0	0%

Table 2: Effect of *G. kola* treatments on adrenal gland oxidative and antioxidant markers.

Groups	Adrenal gland tissue oxidative stress markers		Adrenal gland tissue antioxidant marker	
	MDA (U/ng protein)	Proteins (mg/ml)	SOD (U/mg protein)	CAT (U/mg protein)
Control	3.83±0.28	4.76±0.25	45.54±5.87	371.91±33.90
1000mg/kg <i>G.K</i> Rx	3.14±0.24	4.21±0.12	53.84±3.98	402.57±31.91
1200mg/kg <i>G.K</i> Rx	2.87±0.05	3.11±0.05	61.24±4.62*	438.53±38.76*
1400mg/kg <i>G.K</i> Rx	2.13±0.08*	2.03±0.02*	76.79±4.72*	491.83±27.55*

Note: Mean ± SEM of 5 male rats per group, * = p<0.05 compared to control.

Figure 2 represents the effect of *G. kola* treatments on testicular weight. There was a non-significantly dose depended increase (p>0.05) in testicular weight with graded dose of *G. kola* treatments compared to the control. Table 3 presents the effect of *G. kola* treatments on testicular tissue oxidative and antioxidant marker activities. There was dose dependent decrease in testicular tissue MDA and protein levels that were significant (p<0.05) in the 1400mg/kg *G. kola* treated group compared to the control. Testicular tissue SOD and CAT activities were significantly increased (p<0.05)

in a dose dependent fashion compared to the control. Histological findings on testicular tissue (Plate 2) showed comparable normal spermatogonia cells in the seminiferous tubules epithelium, normal spermatocytes, spermatids and interstitial leydig cells in the *G. kola* treated groups with the control. However, there was a dose dependent germ cells development within the lumen in the *G. kola* treated groups compared to the control with mild congestion (white arrow) in the 1400mg/kg treated group.

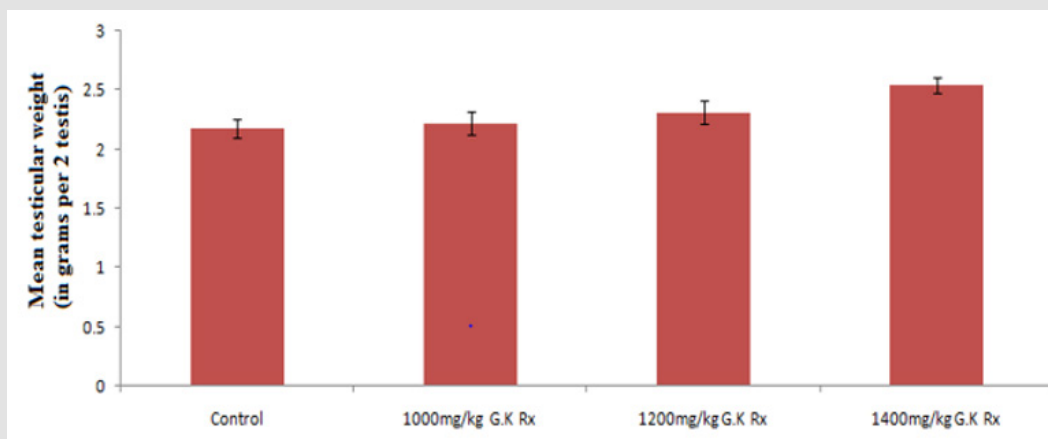


Figure 2: Effect of *G. kola* treatments on testicular weight.

Note: Mean ± SEM of 5 male rats per group.

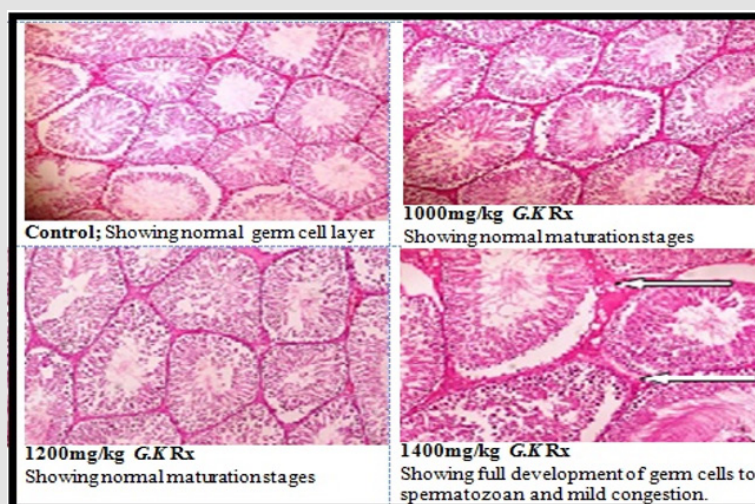


Plate 2: Effect of *G. kola* treatments on testicular tissue histology (Haematoxylin and Eosin stained x100).

Table 3: Effect of *G. kola* treatments on testicular tissue oxidative and antioxidant markers.

Groups	Testicular tissue oxidative stress markers		Testicular tissue antioxidant marker	
	MDA (U/ng protein)	Proteins (mg/ml)	SOD (U/mg protein)	CAT (U/mg protein)
Control	6.51±1.04	5.15±0.34	59.24±4.92	400.86±21.60
1000mg/kg <i>G.K</i> Rx	5.88±1.07	4.97±0.27	73.13±6.78*	505.13±23.06*
1200mg/kg <i>G.K</i> Rx	5.17±0.78	4.01±0.19	77.39±6.83*	571.96±20.58*

Note: Mean ± SEM of 5 male rats per group, * = p<0.05 compared to control.

Discussion

Reactive oxygen species are considered to be unavoidable by-products of normal aerobic metabolism, however, when not balance, they can disrupt cellular homeostasis [18]. In the present study the ingestion of *G. kola* in normal adult male Wistar rat stimulated adrenal gland and testicular weights although not significantly different from the control. In line with this observation, Mosunmola et al. [5] has also reported no significant differences in the testicular weight between control and *G. kola* extract treated rats not exposed to arsenate. Also observed in the present study, the ingestion of *G. kola* in normal adult male Wistar rat weakens the oxidative stress activities and improved antioxidants status of the adrenal gland and testicular tissues in a dose dependent manner. Abarikwu et al. [29] have reported increase mRNA expression of SOD in culture interstitial leydig cells in the present of kolaviron.

The antioxidant and scavenging activity of Garcinia biflavonoid complex has been investigated in a range of established *in vitro* assays involving reactive oxygen species and studies showed that kolaviron elicited significant reducing power and a dose-dependent inhibition of oxidation of linoleic acid [30], reduced damage to proteins and lipids induced by Fe³⁺/EDTA/ascorbate mixtures *ex vivo* [31] as well as caused reduced background levels of protein oxidation marker in plasma and liver and γ -glutamyl semialdehyde (GGS) and malondialdehyde in liver [32]. The inhibitory activity of kolaviron in deoxyribose assay was suggested to directly relate to prevention of the propagation of the process of lipid peroxidation and modulation of other biomarkers of oxidative stress in animal model [33,34]. Thus, the observed decreased in adrenal and testicular oxidative stress markers in this study is in line.

Histological, the graded doses of *G. kola* have no effect on the adrenal gland but 1400mg/kg resulted in a full germ cells development and mild congestion on the testis. In comparison with the findings of this study on the histology of the adrenal gland, Mosunmola et al. [5] has reported comparable number of basophils with the control group in groups not exposed to arsenate. Also in line with the findings on the testis, the study by Mosunmola et al. [5] has reported prominent and healthy spermatogonia in rats unexposed to arsenat but treated with *G. kola* extract and was concluded that the extract improved initiation of spermatogenesis. The observed non significant effect of *G. kola* on the histology of the adrenal gland indicates that the extract is safe. On the other

hand, the improved development on the germ cells of the testis by the ingestion of *G. kola* indicates that the extract stimulates spermatogenesis probably via enhancing hormonal interplay that promote germ cells development through its phytochemical and antioxidant properties.

It is known that plants use a diverse array of anti-oxidative enzymes as well as low molecular weight antioxidants to scavenge different types of reactive oxygen intermediates, thereby protecting cells against injury and potential damage [18]. Thus, the observed effects of *G. kola* on the adrenal gland and testis may be due to its phytochemical and antioxidants components. In support of this assertion, Okoko [35] has previously reported *G. kola* to be a powerful antioxidant. Also, the cytoprotective activity of flavonoids; a phytochemical in *G. kola*, has been reported to be via direct antioxidant effect [36,37]. In fact, flavonoids are documented to possess indirect antioxidant activity through inducing the up-regulation of glutathione, γ -glutamylcystein ligase, glutathione s-transferase and NAD (P) H: quinone oxidoreductase in different cell systems and inhibit cell death by suppressing oxidative stress [38]. Thus, the observed boosting of the adrenal and testicular tissue antioxidant status and weakness of oxidative markers in this study are in accordance and is owned to the antioxidants and phytochemical properties of *G. kola*.

References

1. Uko O J, Usman A, Ataja AM (2001) Some biological activities of *Garcinia kola* in growing rats. *Veterinarski Arhiv* 71(5): 287-297.
2. Iwu MM (1993) Handbook of African medical plants. Bola Raton: CRC Press Inc pp. 223-224.
3. Iwu MM, Igboko OA, Okunji CO, Tempesta MS (1990) Anti-diabetic and aldose reductase activities of biflavanones of *Garcinia kola*. *J. Pharmacy and Pharmacology* 42: 2903-2922.
4. Olayinka OA, Saburi AA, Thomas OI, Oluwakemi CO, Oyesiku AO, et al. (2008) Clinical effects of *Garcinia kola* in knee osteoarthritis. *J Orthop Surg* 3: 34.
5. Mosunmola BO, Isaac OA, Efere MO, Rufus OA, Olugbenga AA (2017) Assessment of the Effects of Graded Doses of Polyphenolic-Rich Fraction of *Garcinia kola* Seeds on Pituitary-Testicular Axis of Male Wistar Rats. *Dose Response* 15(4): 1-8.
6. Tcheghebe TO, Signe M, Seukey JM, Tatong FN (2016) Review on traditional uses, phytochemical and pharmacological profiles of *Garcinia kola* Heckel. *Merit Research Journal of Medicine and Medical Sciences* 4(11): 480-489.
7. Esimone CO, Adikwu MU, Nworu CS, Okoye FBC, Odimegwu DC (2007) Adaptogenic potentials of *Camellia sinensis* leaves, *Garcinia kola* and *Kola nitida* seeds. *Science Research Essays* 2: 232-237.

8. Seanego CT, Ndir RN (2012) Identification and antibacterial evaluation of bioactive compounds from *Garcinia kola* (Heckel) seeds. *Molecules* 17(6): 6569-6584.
9. Antia BS, Pansanit A, Ekpa OD, Ekpe UJ, Mahidol C, et al. (2010) Alpha-glucosidase inhibitory, aromatase inhibitory and antiplasmodial activities of a biflavonoid GB1 from *Garcinia kola* stem bark. *Planta Medica* 76(3): 276-277.
10. Adaramoye OA, Farombi EO, Adeyemi EO, Emerole GO (2005) Inhibition of human low-density lipoprotein oxidation by flavonoids of *Garcinia kola* seeds. *Pakistan J Med Sci* 21(3): 331-339.
11. Lacmata ST, Kuete V, Dzoyem JP, Tankeo SB, Teke GN, et al. (2012) Antibacterial activities of selected cameroonian plants and their synergistic effects with antibiotics against bacteria expressing MDR phenotypes. *Evidence Based Complementary and Alternative Medicine* pp. 11.
12. Obi AU, Nwoha PU (2014) Effects of Kolaviron, the Major Constituent of Garciniakola, on the Histology of the Hypothalamus, Pituitary, and Testes Using Adult Male Wistar Rats as a Model Organism. *Forensic Medicine and Anatomy Research* 2: 80-87.
13. Mazi EA, Okoronkwo KA, Ibe UK (2013) Physico-Chemical and Nutritive Properties of Bitter Kola (*Garcinia kola*). *J. Nutrition and Food Sciences* 3: 218-224.
14. Odebunmi EO, Oluwanli OO, Awolola GV, Adediji OD (2009) Proximate and nutritional composition of Kola nut (*Cola nitida*), bitter kola (*Garcinia kola*), and Alligator pepper (*Aframomum melegueta*). *African Journal of Biotechnology* 8(2): 308-310.
15. Steinmetz KA, Potter JD (1996) Vegetables, fruit, and cancer prevention: a review. *J Am Diet Assoc* 96(10): 1027-1039.
16. Block G (1992) The data support a role for antioxidants in reducing cancer risk. *Nutr Rev* 50(7): 207-213.
17. Hertog MG, Feskens EJ, Hollman PC, Katan MB, Kromhout D (1993) Dietary antioxidant flavonoids and risk of coronary heart disease: the Zutphen Elderly Study. *Lancet* 342(8878): 1007-10011.
18. Mittler R (2002) Oxidative stress, antioxidants and stress tolerance. *Trends Plant Sci* 7(9): 405-410.
19. Vasunilashorn S, Cohen AA (2014) Stress Responsive Biochemical Anabolic/Catabolic Ratio and Telomere Length in Older Adults. *Biodemography Soc Biol* 60(2): 174-184.
20. Hatano O, Takakusu A, Nomura M, Morohashi K (1996). Identical origin of adrenal cortex and gonad revealed by expression profiles of Ad4BP/SF-1. *Genes Cells* 1: 663-671.
21. Heikinheimo M, Pihlajoki M, Schrade A, Kyrönlahti A, Wilson BD (2015) Testicular steroidogenic cells to the rescue. *Endocrinology* 156(5): 1616-1619.
22. Lorke D (1983) A new approach to practical acute toxicity testing. *Archives of Toxicology* 54: 275-287.
23. Ahumibe AA, Braide BV (2009) Effect of gavage treatment with pulverised *garcinia kolaseeds* on erythrocyte membrane integrity and selected haematological indices in male albino Wistar rats. *Nig J Physiological Sciences* 24 (1): 47-52.
24. Nwaopara AO, Anibeze CIP, Akpuaka FC (2010) Histological signs of neurodegeneration in the cerebrum of rats fed with diet containing Yaji: The complex Nigerian suya meat sauce. *Asian J Med Sci* 2(1): 16-21.
25. Gornall AG, Bardawill CJ, David MM (1949) Determination of serum proteins by means of the biuret reaction. *J Biol Chem* 177(2): 751-766.
26. Varshney R, Kale RK (1990) Effects of Calmodulin Antagonists on Radiation-induced Lipid Peroxidation in Microsomes. *Int. J Rad Biol* 58: 733-743.
27. Misra HP, Fridovich I (1972) The role of superoxide anion in the autoxidation of epinephrine and a simple assay for superoxide dismutase. *J Biol Chem* 247: 3170-3175.
28. Sinha KA (1972) Colorimetric Assay of Catalase. *Analytical Biochemistry* 47(2): 389-394.
29. Abarikwu SO, Farombi EO, Pant AB (2012) Kolaviron biflavanoids of *Garcinia Kola* seeds protect atrazine-induced cytotoxicity in primary cultures of rat leydig cells. *Int J Toxicol* 31(4): 407-415.
30. Farombi EO, Akanni OO, Emerole GO (2002) Antioxidative and scavenging activities of kolaviron *in vitro*. *Pharm Biol* 40: 107-116.
31. Farombi EO, Møller P, Dragsted LO (2004) Ex-vivo and *in vitro* protective effects of kolaviron against oxygen-derived radical-induced DNA damage and oxidative stress in human lymphocytes and rat liver cells. *Cell Biol Toxicol* 20(2): 71-82.
32. Farombi EO, Hansen M, Ravn Haren G, Møller P, et al. (2004) Commonly consumed and naturally occurring dietary substances affect biomarkers of oxidative stress and DNA damage in healthy rats. *Food Chem Toxicol* 42(8): 1315-1322.
33. Farombi EO, Tahnteng JG, Agboola AO, Nwankwo JO, Emerole GO (2000) Chemoprevention of 2-acetylaminofluorene-induced hepatotoxicity and lipid peroxidation in rats by kolaviron a *Garcinia kola* seed extract. *Food Chem Toxicol* 38(6): 535-541.
34. Farombi EO (2000) Mechanisms for the hepatoprotective action of kolaviron: studies on hepatic enzymes, microsomal lipids and lipid peroxidation in carbontetrachloride-treated rats. *Pharmacol Res* 42(1): 75-80.
35. Okoko T (2009) *In vitro* antioxidant and free radical scavenging activities of *Garcinia kola* seeds. *Food Chem. Toxicol* 47(10): 2620-2623.
36. Chen TJ, Jeng JY, Lin CW, Wu CY, Chen YC (2006) Quercetin inhibition of ROSdependent and-independent apoptosis in rat glioma C6 cells. *Toxicol* 223(2): 113-126.
37. Chow JM, Shen SC, Huan SK, Lin HY, Chen YC (2005) Quercetin, but not rutin and quercitrin, prevention of H₂O₂-induced apoptosis via antioxidant activity and heme oxygenase 1 gene expression in macrophages. *Biochem Pharmacol* 69: 1839-1851.
38. Ayepola OR, Cerf ME, Brooks NL, Oguntibeju OO (2014) Kolaviron, a biflavonoid complex of *Garcinia kola* seeds modulates apoptosis by suppressing oxidative stress and inflammation in diabetes-induced nephrotoxic rats. *Phytomed* 21: 1785-1793.

ISSN: 2574-1241

DOI: 10.26717/BJSTR.2020.29.004754

Osifo CU. Biomed J Sci & Tech Res



This work is licensed under Creative Commons Attribution 4.0 License

Submission Link: <https://biomedres.us/submit-manuscript.php>

Assets of Publishing with us

- Global archiving of articles
- Immediate, unrestricted online access
- Rigorous Peer Review Process
- Authors Retain Copyrights
- Unique DOI for all articles

<https://biomedres.us/>