

Venaseal™ Cyanoacrylate Glue Rejection Following Endovenous Ablation - Another New Complication

PS Lew¹, YK Tan¹, TT Chong² and TY Tang*²

¹Department of General Surgery, Changi General Hospital, Singapore

²Department of Vascular Surgery, Singapore General Hospital, Singapore

*Corresponding author: TY Tang, Consultant Vascular & Endovascular Surgeon, Associate Professor Duke-NUS Medical School, Department of Vascular Surgery, Singapore General Hospital, Level 5; Academia, 20 College Road, Singapore



ARTICLE INFO

Received: 📅 April 20, 2019

Published: 📅 May 02, 2019

Citation: PS Lew, YK Tan, TT Chong, TY Tang. Venaseal™ Cyanoacrylate Glue Rejection Following Endovenous Ablation - Another New Complication. Biomed J Sci & Tech Res 17(4)-2019. BJSTR. MS.ID.003040.

ABSTRACT

Abbreviations: CVI: Chronic Venous Incompetence; GSV: Great Saphenous Vein; SSV: Small Saphenous Vein

Introduction

The VenaSeal™ closure system (Medtronic, Minnesota, USA) is a medical tissue adhesive containing n-butyl-2 cyanoacrylate, injected endovenously to treat varicose veins and superficial chronic venous incompetence (CVI), resulting here in a new treatment -related complication. This 42-year-old Malay male underwent endovenous ablation of the right great saphenous vein (GSV) and small saphenous vein (SSV) in November 2017 with the device for CEAP 6 disease. He had no previous drug allergies. The procedure was uneventful but unfortunately he started developing multiple painless large 'pustules' with surrounding erythema along the treated GSV and SSV 2 weeks post-operatively. This was initially thought to be a phlebitic type reaction, which is common side-effect after this procedure [1]. The patient was treated with anti-inflammatories and antibiotics assuming an element of underlying infection. However, his infection markers were never raised. All the pustules eventually burst and to our surprise pieces of white glue casts were seen from each wound (Figure 1). Histology of the glue cast showed degenerative inflammatory debris [2]. Subsequently, more glue casts were extruded periodically over the next 6-12 months until all the wounds were healed completely (Figure 2). Surveillance ultra

sound scan at 12 months showed that both GSV and SSV remained completely ablated (Figure 3). Patient remained asymptomatic from his treated CVI.

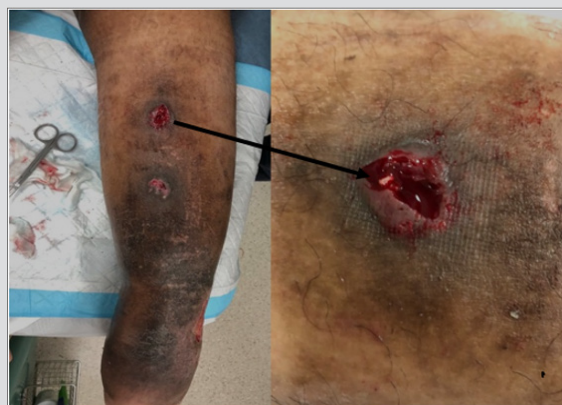

Figure 1: Left panel shows wounds on the calf following Venaseal ablation and glue cast is visible on the wounds overlying the LSV. Right panel is a close-up of the wound showing a frond of CAG protruding from the underlying great saphenous vein.

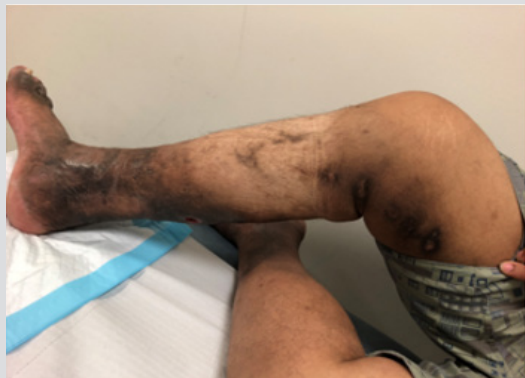

Figure 2: Multiple healed wounds along the distribution of GSV. Those wounds were extruding glue casts and took about 8 months to heal completely.

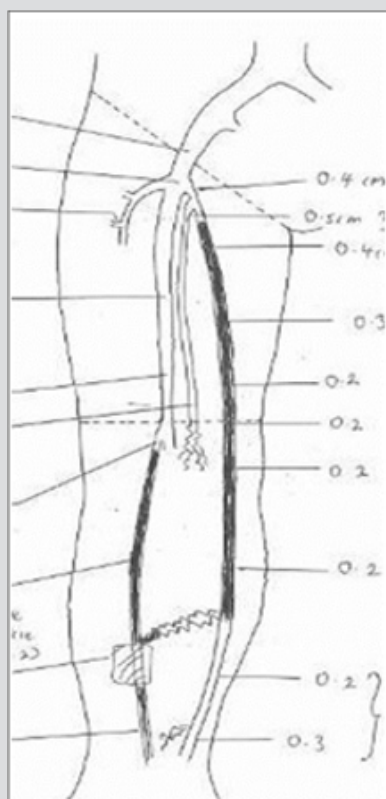


Figure 3: Venous duplex scan of right lower limb, 12 months after the Venaseal procedure, showing obliteration of GSV and LSV.

Discussion

Hypersensitive reaction to cyanoacrylate has been reported when used as topical skin adhesive in place of traditional sutures for post-surgical wounds [3] and as cosmetic adhesive, for example, fixation of wigs [4]. To the best knowledge of authors, this phenomenon associated with use of glue for treating varicose veins has never been reported in the literature. The authors believe this is likely to be a hypersensitivity reaction to cyanoacrylates rather than infection-based on the clinical presentation. In this patient, there were no significant adverse outcome in wound healing and the efficacy of the treatment apart from the post-inflammatory hyperpigmentation. Allergy reactions to cyanoacrylate skin adhesive can be managed by immediate removal of the adhesive. However, for VenaSeal, removal of the glue casts involves surgical intervention and therefore the implication may be more significant. This case has illustrated the natural history of hypersensitivity to cyanoacrylate may present when it is used for treatment of varicose veins. The senior author (TYT) no longer offers this option of venous ablation to patients with multiple drug allergies as he has found that a hypersensitivity reaction is more likely in these types of patients.

References

1. Tang TY, Tiwari A (2018) The VenaSeal™ Abnormal Red Skin Reaction: Looks Like but is not Phlebitis!. *Eur J Vasc Endovasc Surg* 55(6): 841.
2. Tang TY (2018) Endovenous Cyanoacrylate Super-Glue to Treat Varicose Veins: How I Perform VenaSeal Ablation - Tips & Tricks Gained from Ablating Over 300 Truncal Saphenous Veins. *Annals Vasc Med Surg* 1(1): 1-5.
3. Bowen C, Bidinger J, Hivnor C, Hoover A, Henning JS (2014) Allergic Contact Dermatitis to 2-Octyl Cyanoacrylate. *Cutis* 94(4): 183-186.
4. Sornakumar L, Shanmugasekar C, Rai R, Priya S (2013) Allergic Contact Dermatitis to Superglue. *Int J of Trichology* 5(1): 43-44.

ISSN: 2574-1241

DOI: 10.26717/BJSTR.2019.17.003040

TY Tang. Biomed J Sci & Tech Res



This work is licensed under Creative Commons Attribution 4.0 License

Submission Link: <https://biomedres.us/submit-manuscript.php>



Assets of Publishing with us

- Global archiving of articles
- Immediate, unrestricted online access
- Rigorous Peer Review Process
- Authors Retain Copyrights
- Unique DOI for all articles

<https://biomedres.us/>