

Hepatitis C and Neurological Disorders A Patient's Case Report

A Aomari*, M Firwana, I Benelbarhdadi and FZ Ajana

Department of Gastroenterology and liver diseases, IBN SINA University hospital, Africa

Received: August 07, 2017; Published: August 23, 2017

*Corresponding author: A Aomari, Department of Gastroenterology and liver diseases, medicine C, IBN SINA University hospital, Rabat, Africa

Abstract

Introduction: Neurological disorders associated with hepatitis C is most often related to mixed cryoglobulinemia. The aim of this study is to show the severity of neurological disorders during hepatitis c infection.

Observation: Mrs. S A, 60 years old, who had been in purpuric rash for six months, associated with physical and psychic asthenia and weight loss at 16 kg in 8 months. The evolution was marked by an alteration of the neurological state of the patient with an installation of motor deficit affecting the 04 limbs, abolition of the osteo-tendinous reflexes, and a hypoesthesia of the upper and lower limbs. The electromyogram (EMG) showed a sensori-motor polyradiculo neuropathy, and the etiological diagnosis was in favor of a peripheral neuropathy secondary to a cryoglobulinemia, related to hepatitis c. In addition, the patient presented after a few days of headaches, a sharp drop in visual acuity and high blood pressure, this is complicated by two episodes of convulsive seizures. A cranial CT scan is performed in an emergency without abnormalities, with no sign in relation to thrombophlebitis after injection of contrast agent. The diagnosis retained is a central neurological disease secondary to infection with the virus c associated with peripheral neurological disease.

Conclusion: Neurological disorders associated with hepatitis C are rare but poor prognosis threatening the functional and vital prognosis of patients.

Keywords : Hepatitis C; Mixed Cryoglobulinemia; Neurological Disorders

Introduction

Hepatitis C is an infectious disease that affects the liver with predilection but also affects other organs, and is thus considered a disease of the system. Neurological damage associated with hepatitis C is most often related to mixed cryoglobulinemia, typically peripheral, sometimes central, and poor prognosis [1]. The aim of our work is to show through an observation the severity of neurological damage during hepatitis c infection.

Case Report

Mrs. S A, 60 years old, who had been in purpuric rash for six months, associated with physical and psychic asthenia and weight loss of 16 kg in 8 months. The evolution was marked by an alteration of the neurological state of the patient with an installation of motor deficit affecting the four limbs, abolition of the osteo-tendinous reflexes, and a hypoesthesia of the upper and lower limbs. The electromyogram (EMG) showed a sensori-motor polyradiculoneuropathy, and the etiological diagnosis was in favor of a peripheral neuropathy secondary to a cryoglobulinemia, related to hepatitis c (The viral load is 100.000 ui/ml). In addition, the patient presented after a few days of headaches, a sharp drop

in visual acuity and high blood pressure, this is complicated by two episodes of convulsive seizures.

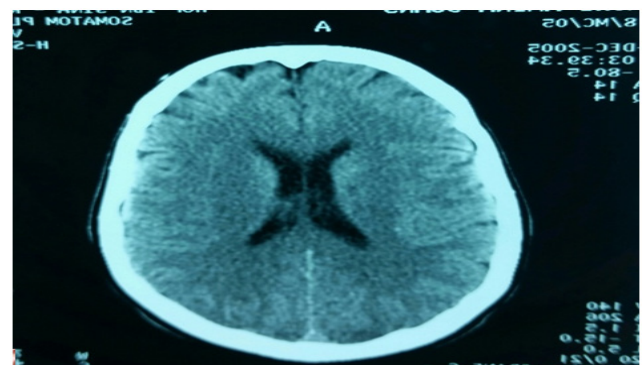


Figure 1: Cranial CT scan normal, without abnormalities.

A cranial CT scan (Figure 1) is performed in an emergency without abnormalities, with no sign in relation to thrombophlebitis after injection of contrast agent. The diagnosis retained is a central neurological disease secondary to infection with the virus c associated with peripheral neurological disease (Figure 1). The

evolution was unfavorable, and the patient died in intensive care six hours after admission. The cause of death was a sudden cardiac arrest despite cardiopulmonary resuscitation. The patient was deceased without the benefit of MRI imaging.

Comment

Neurological manifestations in hepatitis C are present in 9 to 45% of cryoglobulinemics, [2-4] the predominant clinical form in 70% of cases is that of sensory or sensory-motor polyneuropathy predominant to the lower limbs, more rarely (30%) mononeuropathy or multiple mononeuropathy [4,5]. The prolonged evolution is by pushes, with stabilization, remission or exacerbation of symptoms sometimes triggered by exposure to cold. The electromyogram of the four limbs confirms the axonal neuropathy with alterations of the sensory and / or motor potentials, or even of the motor conduction. Rarely, cryoglobulinaemia associated with hepatitis C may be complicated with other types of peripheral neuropathies, such as polyradiculoneuritis. Central neurological disease is characterized by encephalopathies, convulsions, cerebral vasculitis with cerebral infarction and cranial palsy [6].

Alterations in upper functions have been reported, including cognitive and attention deficits, associated or not with depressive syndrome or chronic fatigue syndrome. These central neurological manifestations are rare and poor prognosis in relation to peripheral manifestations [7]. Our case reports a case of peripheral and central neurological disorders during a cryoglobulinemia with chronic viral hepatitis C, which was severe in causing sensory-motor deficit with abolition of the osteo-tendinous reflexes, explained by an important alteration of the nerve roots of the two upper and lower limbs.

Central nervous system disorders began with decreased visual acuity, arterial hypertension and headache, which was rapidly aggravated by two episodes of convulsive seizures with altered consciousness. The evolution was fatal and the patient died a few hours after admission to intensive care, this reinforces the data of the literature concerning the severity of the central neurological manifestation. In addition, several cohort studies have shown the existence of epidemiological, clinical and biological factors strongly associated with the production of mixed cryoglobulinemia during chronic hepatitis C virus infection, including female sex, advanced age, Genotype 2 or 3 and extensive liver fibrosis [8,9]. Two of these factors are present in our case and which have led to the diagnosis of an extrahepatic disorders of hepatitis C.

Conclusion

Our patient illustrates the case of an exceptional neurological localization and a rare association of mixed cryoglobulinemia with chronic viral hepatitis C. This rare localization is a poor prognosis threatening both functional and vital prognosis.

Explanation of terms

Asthenia: debility, loss of strength and energy, weakness.

Poly radiculo neuropathy

Literally: A disease process that affects roots and peripheral nerves. A non traumatic, usually sporadic, generalized disorder of nerve roots and peripheral nerves, which may affect motor fibers or sensory fibers, but usually both, although often not to the same degree; classified as axon degenerating (axonal) or demyelinating. This disorder has many causes, primarily immune mediated, and includes Guillain-Barré syndrome and chronic inflammatory polyneuropathy.

Mixed cryoglobulinemia

Mixed cryoglobulinemia is a medical condition in which the blood contains large amounts of cryoglobulins-proteins (mostly immunoglobulins themselves) that become insoluble at reduced temperatures. This should be contrasted with cold agglutinins, which cause agglutination of red blood cells. Cryoglobulins typically precipitate at temperatures below normal body temperature (37 °C) and will dissolve again if the blood is heated. The precipitated clump can block blood vessels and cause toes and fingers to become gangrenous. Cryoglobulinemia can be associated with various diseases such as multiple myeloma and hepatitis C infection [2]. Cryoglobulins usually consist of IgM directed against the Fc region of IgG.

Hypoesthesia

Refer to a reduced sense of touch or sensation, or a partial loss of sensitivity to sensory stimuli. In every day speech this is sometimes referred to as "numbness". Hypoesthesia is one of the negative sensory symptoms associated with cutaneous sensory disorder (CSD). In this condition, patients have abnormal disagreeable skin sensations that can be increased (stinging, itching or burning) or decreased (numbness or hypoesthesia). There are no other apparent medical diagnoses to explain these symptoms.

Thrombophlebitis

Thrombophlebitis is phlebitis or vein inflammation related to a thrombus, which is a blood clot [1]. When it occurs repeatedly in different locations, it is known as thrombophlebitismigrans, (migrating thrombophlebitis) indicated by the Trousseau sign of malignancy.

Encephalopathies

Encephalopathies means disorder or disease of the brain. In modern usage, encephalopathy does not refer to a single disease, but rather to a syndrome of overall brain dysfunction; this syndrome can have many different organic and inorganic causes.

References

1. Ferri C, Lacivita L, Cirafisi C (1992) peripheral neuropathy in mixed cryoglobulinemia clinical and electrophysiologic investigations. *J Rheumatol* 19(6): 889-895.
2. Cacoub P, Renou C, Rosenthal E, Cohen P, Lhoury I, et al. (2000) Extrahepatic manifestations associated with hepatitis C virus infection. A prospective multicenter study of 321 patients. *Medicine (Baltimore)* 79(1): 47-56.

3. Sène D, Ghillani-Dalbin P, Thibault V, Guis L, Musset L, et al. (2004) Longterm course of mixed cryoglobulinemia in patients infected with hepatitis C virus. *J Rheumatol* 31(11): 2199-2206.
4. Nemni R, Sanvito L, Quattrini A, Santuccio G, Camerlingo M, et al. (2003) Peripheral neuropathy in hepatitis C virus infection with and without cryoglobulinaemia. *J Neurol Neurosurg Psychiatry* 74(9): 1267-1271.
5. Cacoub P, Maissonobe T, Thibault V, Gatel A, Servan J, et al. (2001) Systemic vasculitis in patients with hepatitis C. *J Rheumatol* 28(1): 109-118.
6. Casato M, Lilli D, Donato G, Granata M, Conti V, et al. (2003) Occult hepatitis C virus infection in type II mixed cryoglobulinaemia. *J Viral Hepat* 10(6): 455-459.
7. Casato M, Saadoun D, Marchetti A, Piscq C, Pantano P, et al. (2003) Central Nervous System Involvement in HCV-Cryoglobulinemia Vasculitis: a Multicenter Case-Control Study using MRI and Neuropsychological Tests. *Arthritis Rheum* (48): S522.
8. Cacoub P, Renou C, Rosenthal E, Cohen P, Louri I, et al. (2000) Extrahepatic manifestations associated with hepatitis C virus infection. A prospective multicenter study of 321 patients. *Medicine (Baltimore)* 79(1): 47-56.
9. Saadoun D, Asselah T, Resche-Rigon M, Charlotte F, Bedossa P, et al. (2006) Cryoglobulinemia is associated with steatosis and fibrosis in chronic hepatitis C. *Hepatology* 43(6): 1337-1345.



Assets of Publishing with us

- Global archiving of articles
- Immediate, unrestricted online access
- Rigorous Peer Review Process
- Authors Retain Copyrights
- Unique DOI for all articles

<http://biomedres.us/>