

Unilateral Genital Hypertrophy in Boys and Girls: Tumor Mimics in Pediatrics

**Masahiro kitami****Department of Diagnostic Radiology, Tohoku University Graduate School of Medicine, Japan***Received:** May 27, 2018; **Published:** June 05, 2018***Corresponding author:** Masahiro Kitami, Department of Diagnostic Radiology, Tohoku University Graduate School of Medicine, 2-1 Seiryō-cho, Sendai, 980-8574 Japan

Abstract

Unilateral genital hypertrophy is a rare phenomenon that can occur in both sexes. In view of its rarity and laterality, genital hypertrophy can be misdiagnosed as malignancy, resulting in unnecessary biopsy or surgery. Therefore, correct recognition of these tumor mimics is important. This article describes representative pediatric cases of childhood asymmetric labium majus enlargement (CALME) and unilateral enlargement of the testis. The radiologic hallmark of CALME is unilateral swelling of the labium majus with heterogeneous signal intensity and low-intensity strands on magnetic resonance imaging. Homogenous enlargement is the key feature of unilateral enlargement of the testis.

Keywords: Unilateral Genital Hypertrophy; Physiologic Finding; Hypertrophy; Labia; Vulva; Testis; Swelling; Enlargement; Overgrowth; Hyperplasia

Abbreviations: CALME: Childhood Asymmetric Labium Majus Enlargement; MRI: Magnetic Resonance Imaging

Introduction

Unilateral vulval or testicular hypertrophy is a phenomenon peculiar to puberty. It is a physiologic hormonal response and do not require surgical intervention. However, given its rarity and laterality, this entity can be easily misdiagnosed as a malignant tumor, potentially resulting in unnecessary biopsy or surgery. Therefore, recognition of this phenomenon is important. This article presents two representative cases and discusses the key points for correct diagnosis.

Case 1

A 10-year-old girl was referred to our hospital with a unilateral vulval “mass” after a right inguinal-vulval bulge had been noticed 3 years earlier. At the time of medical examination, the bulge had decreased in size, and an inguinal hernia or hydrocele was suspected. A conclusive diagnosis could not be made even after sonography, so the recommendation was to keep the bulge under observation. She then re-visited the hospital because of an increase in the size of the bulge. However, at the time of examination, the bulge had again decreased in size.

Magnetic resonance imaging (MRI) performed to rule out an inguinal hernia or hydrocele revealed swelling of the labium majus with heterogeneous intensity and low-intensity strands on T1-weighted and T2-weighted images (Figure 1). Despite the vulval swelling, the margin was obscure and there was no discrete mass.

A diffusion-weighted image showed no restriction. Sonography showed heterogeneous echogenicity with no discrete mass (not shown). There were no laboratory data suggestive of malignancy, such as elevated tumor marker levels. Based on the clinical and radiologic findings, a diagnosis of childhood asymmetric labium ma-

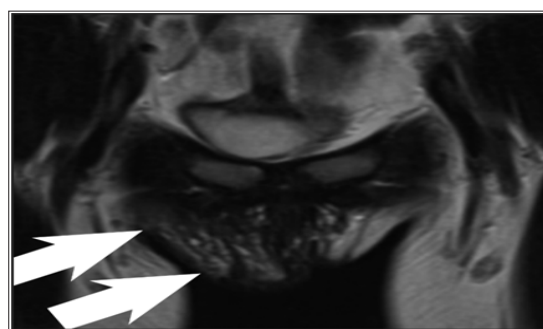


Figure 1: A 10 year-old girl with childhood asymmetric labium majus enlargement (CALME)

A coronal T2-weighted image shows swelling of the right labium majus without a discrete mass (arrows). The lesion shows heterogeneous intensity with low-intensity internal strands. A diagnosis of childhood asymmetric labium majus enlargement was made on the basis of the radiological findings and clinical course that included fluctuating size and the absence of laboratory findings suggesting malignancy.

Case 2

An 11-year-old boy presented with a complaint of painless right testicular swelling that had been present for 2 months. Sonography performed to exclude a testicular tumor revealed a homogenous swelling in the right testicle but no detectable mass. MRI also showed a right-sided homogenous testicular swelling with no mass (Figure 2). Laboratory investigations did not reveal elevated tumor markers. A diagnosis of unilateral enlargement of the testis was made on the basis of the radiologic and laboratory findings.

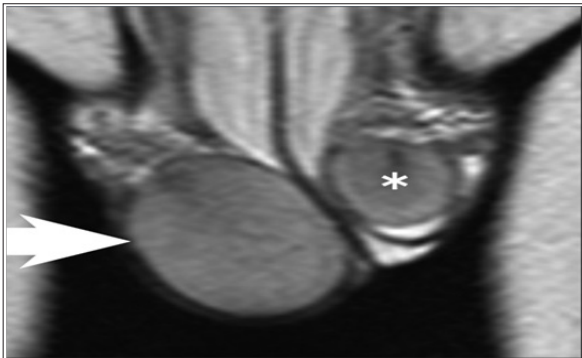


Figure 2: An 11 year-old boy with unilateral enlargement of the testis.

A coronal T2-weighted image shows a homogenous right testicular swelling (arrow) when compared with the normal side (asterisk) without a mass. A diagnosis of unilateral enlargement of the testis was made on the basis of radiological homogeneity and the absence of laboratory findings suggesting malignancy.

Discussion

Unilateral vulval and testicular hypertrophy are rare phenomena encountered in pediatrics. Both entities could be misdiagnosed as malignancy, leading to unnecessary investigations and surgical procedures. These phenomena are not widely recognized by clinicians and radiologists. However, recognition of these entities is crucial to avoid unnecessary invasive procedures. CALME is also known as prepubertal unilateral fibrous hyperplasia, vulvar hamartoma, prepubertal vulval fibroma, and fibrous hyperplasia of the labium majus [1]. Prepubertal or pubertal unilateral hypertrophy of the labium majus is the hallmark of CALME. The etiology is not fully understood; however, it has been suggested that CALME could be a physiologic enlargement in response to hormonal surges in pre-puberty and early puberty [2]. A clinical course of enlargement and reduction, which might mislead clinicians to misdiagnose an inguinal hernia, as in our cases, could be explained by physiologic fluctuations on hormone levels.

The pathology typically shows non-specific findings of spindle-shaped fibroblasts, prominent elastic fibers and a myxoid extracellular matrix without abnormal cells. Therefore, a pathologic di-

agnosis is difficult to obtain [2,3]. Furthermore, surgical resection is difficult because of an unclear margin, resulting in a recurrence rate of 50% [2]. Therefore, biopsy and surgical resection is not recommended and a conservative approach has been proposed [4]. Sonography and MRI show unilateral ill-defined labial enlargement without a definable mass. MRI also shows hypointense strands on T1-weighted and T2-weighted imaging [1]. Unilateral enlargement also occurs in the testis [5-7]. This phenomenon seems even less well recognized, and does not have specific nomenclature. This is described simply as unilateral enlargement of the testis, transitory unilateral testis enlargement of puberty, unilateral testicular end-organ hypersensitivity, or unilateral asymptomatic testis enlargement.

Although testicular enlargement suggests the possibility of a malignant tumor, completely normal radiologic findings point to a diagnosis of unilateral hypertrophy, and surgical exploration is not required [7]. Differential diagnoses of unilateral testicular enlargement include schistosomiasis, mastocytoma, McCune Albright syndrome, and Beckwith-Wiedemann syndrome. Therefore, both clinical assessment and radiologic evaluation are necessary. Unilateral testicular enlargement could be interpreted as the male counterpart of CALME, given that both are ascribed to hormonal hypersensitivity [7] and mimic malignant tumors.

Conclusion

We have discussed two cases of unilateral genital hypertrophy, one in a boy (unilateral enlargement of the testis) and the other in a girl (CALME). This entity is a tumor mimic in pediatrics and recognition is crucial to avoid unnecessary surgical intervention.

References

- Gokli A, Neuman J, Lukse R, Koshy J, Kong F, Laor T (2016) Childhood asymmetrical labium majus enlargement: sonographic and MR imaging appearances. *Pediatr Radiol* 46(5): 674-679.
- Vargas SO, Kozakewich HP, Boyd TK, et al. (2005) Childhood asymmetric labium majus enlargement: mimicking a neoplasm. *Am J Surg Pathol* 29(8):1007-1016.
- Iwasa Y, Fletcher CD (2004) Distinctive prepubertal vulval fibroma: a hitherto unrecognized mesenchymal tumor of prepubertal girls: analysis of 11 cases. *Am J Surg Pathol* 28(12):1601-1608.
- Soyer T, Hancerliogullari O, Pelin Cil A, Evliyaoglu O, Cakmak M (2009) Childhood asymmetric labium majus enlargement: is a conservative approach available? *J Pediatr Adolesc Gynecol* 22(2):e9-e11.
- De Sanctis V, Marsella M (2011) Unilateral asymptomatic testis enlargement in children and adolescents. *Georgian Med News* (193):25-29.
- Lee PA, Marshall FF, Greco JM, Jeffs RD (1982) Unilateral testicular hypertrophy: an apparently benign occurrence without cryptorchidism. *J Urol* 127(2):329-331.
- MacMahon RA, Cussen LJ (1991) Unilateral enlargement of the testis in childhood: does it need exploration? *J Pediatr Surg* 26(1):68-69.



This work is licensed under Creative Commons Attribution 4.0 License

Submission Link: <https://biomedres.us/submit-manuscript.php>



Assets of Publishing with us

- Global archiving of articles
- Immediate, unrestricted online access
- Rigorous Peer Review Process
- Authors Retain Copyrights
- Unique DOI for all articles

<https://biomedres.us/>