

Effects of the Aqueous Extract of *Cnestis Ferruginea* on the Histological Structure of Female Rat Ovary and Uterine Horns

Zougrou N'guessan Ernest, Blahi Adélaïde Nadia, Kouassi Komenan Daouda and Kouakou Koffi

Department of Bioscience, University Félix Houphouët-Boigny Abidjan, Côte d'Ivoire, Africa

Received: December 18, 2017; Published: January 03, 2018

*Corresponding author: Zougrou N'guessan Ernest, Department of Bioscience, Biology of Reproduction and Endocrinology Laboratory, University Félix Houphouët-Boigny Abidjan, Abidjan, Côte d'Ivoire, Africa; Email: zougrouernest1977@gmail.com

Abstract

Cnestis ferruginea (Connaraceae) is a plant used in the treatment of several affections including "sterility" and increased fertility. This work aims to show the pharmacological effects of the aqueous extract of *Cnestis ferruginea* on the ovary and uterine horn of adult female rats. Thirty-six adult female rats were randomized into 2 sets of 18 each and treated for 15 (set I) and 30 days (set II). Each set was then divided equally into three groups. Group 1 (control) was orally administered with distilled water once a day. Group 2 and group 3 were respectively treated with 50 (AECF₅₀) and 100 mg/kg (EACF₁₀₀) body weight of aqueous extract of *C. ferruginea* orally once a day. 24 hours after the last doses, the rats of each group are sacrificed. The ovary and uterus of each rat are removed and immediately fixed in 10% formalin for histological study. *Cnestis ferruginea* induced a significant ($p < 0.05$) increase in the number of corpus luteum after 15 days of treatment with AECF50. After 30 days of treatment, the number of corpus luteum increased significantly ($p < 0.05$) with both doses administered. Both doses also induced significant increases ($p < 0.05$) with the two treatment durations, the number of De Graaf follicles. The number of tertiary follicles increased significantly ($p < 0.05$) with AECF₁₀₀ after 15 days of treatment. The duration of 30 days allowed recording a significant increase in the number of tertiary follicles with the two doses administered. The other follicles experienced significant increases with AECF100 after 30 days of treatment. For uterine horns, lumen diameters of uterine horns and uterine glands increased significantly ($p < 0.05$) with both doses administered and both durations of treatment. The thickness of the endometrial and the size of the epithelial cells increased significantly ($p < 0.05$) with AECF₁₀₀ after 15 days of treatment. These latter parameters experienced significant increases with both doses administered at the end of 30 days of treatment. In conclusion, *C. ferruginea* stimulates folliculogenesis and induces ovulation in the ovary. On the uterine horn, this plant has estrogenic properties.

Keywords: *Cnestis ferruginea*; Ovary; Uterine horn; Ovulation; Estrogenic

Introduction

Man has been using medicinal plants to treat diseases for millennia. According to estimates, more than two-thirds of the world's plant species are of medicinal value. WHO estimates that about 80% of people living in developing countries depend on traditional medicine for their primary health care needs? About 50 to 60% of pharmaceuticals are of natural origin or are synthesized from natural products [1,2]. However, there are still many plants for which the mode of action, the biological targets and the side effects of the molecules are not yet elucidated. Yet, they are used by a large part of the population to heal themselves. This exposes them to serious and sometimes irreversible damage. It is then necessary to carry out pharmacological research to study the effectiveness of these plants used in traditional medicine. It is in this context that the plant species *Cnestis ferruginea* (Connaraceae) a plant used in the treatment of several affections including "sterility" and increased fertility according Tra Bi [3] and N'guessan et al. [4], caught our attention in this study. This work aims to show the pharmacological

effects of the aqueous extract of *Cnestis ferruginea* on the ovary and uterine horn of adult female rats.

Materials and Methods

Plant Material

Fresh leaves of *Cnestis ferruginea* were harvested in November in the Region of Nawa, Department of Soubré, precisely in the village named Trawininkro (V8) (Côte d'Ivoire). A sample of this plant has been identified and authenticated by Professor Aké-Assi at the Laboratory of Botany and Plant Biology of Université Félix Houphouët-Boigny.

Preparation of Extract

Harvested leaves have been rinsed with distilled water, dried in the shade (sheltered from the sun) at an ambient temperature (24 ± 2 °C). The dried leaves were crushed with a power mill (IKA A10 Labortechnik, Germany) to obtain a powder. The powder

obtained has been macerated by mixing 50g and 1.5L of distilled water and stirred for 24 hours by a magnetic stirrer (Janke & Kuntelika Labortechnik, Germany). After three times filtration on Whatman filter paper number 1, the filtrate was concentrated in an air circulating oven at 50 °C until total dryness. The aqueous extract obtained has been stored at 4 °C in a refrigerator for the experimental studies.

Animal Material

Adult female rats, (*Rattus norvegicus*, Muridae), Wistar strain, virgin, weighing between 130-150 g and aged 55-65 days are from the animal facility of ENS (Ecole Normale Supérieure). These rats have been used for this study of the aqueous extract of *C. ferruginea*. They were raised in stable temperature room (24±2°C). In these premises, the photoperiod was 12 hours and 50-55% humidity. The animals were fed *ad libitum* water, bread, fish, corn and peanuts.

Experimental Design

Thirty-six adult female rats were randomly distributed into 2 sets of 18 animals each and treated for 15 (set I) and 30 days (set II). Each set was then divided equally into three groups and treated as follows: Group 1 (control) was orally administered with distilled water once a day. Group 2 and group 3 were respectively treated with 50 (AECF₅₀) and 100 mg/kg (EACF₁₀₀) body weight of aqueous

extract of *C. ferruginea* orally once a day. 24 hours after the last doses, the rats of each group are sacrificed. The ovary and uterus of each rat are removed and immediately fixed in 10% formalin.

Histological Study

The uterus and ovary harvested and fixed in Formaldehyde 10% were dehydrated in an ascending grade of (ethanol), cleared in toluene and embedded in paraffin wax. Serial sections of 5 microns thick were obtained using a rotatory microtome (Leica RM2125 RTS, Allemagne). The deparaffinised sections of the organs were stained routinely with Harris haematoxyline and eosin (H & E) stain. The analysis of the sections was done using a tri-ocular photonic microscope (Olympus CK41SF, Philippine) connected to a computer. Imaging and image analysis were done using the Videomet software version 8.0.9 (France).

Statistical Analysis

The data and graphical representation of the data was performed using the Graph Pad Prism 5.01 software (Microsoft, USA). The experimental results were expressed as Mean±SEM and data were assessed by the method of analysis of one-way ANOVA followed by Tukey test with least significant test. P value <0.05 was considered significant, P value <0.01 considered highly significant and P value <0.001 considered very highly significant.

Result

Effects of the Aqueous Extract of *Cnestis ferruginea* on Ovarian Organelles

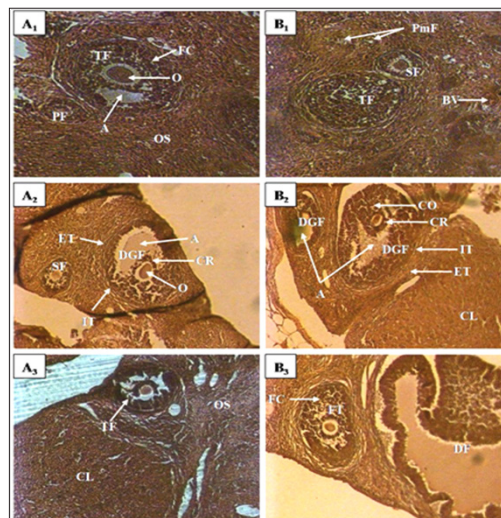


Figure 1: Ovary micrograph of control and treated rats with *Cnestis ferruginea* at 15 and 30 days

A1: Control (15 days).

A2: Treated 50 mg/kg BW (15 days),

A3: Treated 100 mg/kg BW (15 days),

B1: Control (30 days),

B2: Treated 50 mg/kg BW (30 days),

B3: Treated 100 mg/kg BW (30 days)

A: Antrum; FC: Follicular cells; C: Corpus luteum; CR: Corona radiata; DGF: De Graaf's follicle; PF: Primary follicle; PmF: primordial follicle; SF: Secondary follicle; TF: tertiary follicle; O: Oocyte; DF: Dehiscent follicle; OS: Ovarian stroma; ET: External theca; IT: Internal theca; BV: Blood vessel

Table 1: Effect of *Cnestis ferruginea* on ovarian organelles after 15 (set I) and 30 (set II) days of treatment.

Follicle	15 Days			30 Days		
	Control	AECF ₅₀	AECF ₁₀₀	Control	AECF ₅₀	AECF ₁₀₀
corpus luteum	8,33±0,56	11,33±1,09	12,17±0,95*	9,67±0,96	14,67±1,33*	14,17±1,30*
Follicles de De Graaf	2,33±0,42	5,16±0,87*	6,17±0,83**	3,17±0,70	6,67±0,99*	7,83±0,87**
tertiary follicles	2,67±0,56	5,50±0,87	6,17±0,89*	3,33±0,72	6,50±0,89*	7,17±0,87*
Secondary follicles	4,16±0,60	7,33±0,76*	7,50±0,85*	4,83±0,95	8,83±0,87*	8,33±0,76*
Other follicles	24,83±1,91	26,67±2,11	29,50±1,86	23,17±1,96	28,33±1,63	31,50±2,90*

Note: Values are means ± SEM (n=6); * = p<0.05; ** = p<0.01. Control: Distilled water, AECF₅₀: Aqueous Extract of *C. freruginea* (50mg/kg of body weight), AECF₁₀₀: Aqueous Extract of *C. freruginea* (100mg/kg of body weight).

Histological study of rats ovaries treated for 15 days (set I) and 30 days (set II) with the aqueous extract of *C. ferruginea* and the vehicle was carried out (Figure 1) and the results are recorded in the (Table 1). Indeed, animals treated for 15 days with AECF₁₀₀ showed significant increase (p <0.05) of corpus luteum number of 46.05% compared to controls while the increase induced by the low dose is not significant. With the 30-day duration, treatments using AECF₅₀ and AECF₁₀₀ resulted in a significant (p <0.05) increase in corpus luteum number of 51.75% and 46.58%, respectively, compared with controls. Counting of De Graaf follicle showed a significant (p <0.05) increase in its number with AECF₅₀ for both treatment durations. The results made it possible to record a rate of increase of 121.47% and 110.51% respectively for the 15 and 30 day treatment periods. As for AECF₁₀₀, the results showed a very significant increase (P <0.01) of these follicles compared with controls. Thus, a rate of 164.34% and 147.33% increase was recorded respectively for the 15 and 30 day treatment durations. The 15-day treatment with

AECF₁₀₀ resulted in a significant (p <0.05) increase of 131.23% in the number of tertiary follicles compared with controls.

The increase induced by the dose of 50mg/kg of BW is not statistically significant (p > 0.05). With the 30-day treatment, there was a significant increase (p <0.05) of 95.02% and 115.03% respectively for AECF₅₀ and AECF₁₀₀. Regarding the secondary follicles, the extract induced a significant increase (p <0.05) in its number regardless of the dose and duration of treatment. Thus, there is an increase of 75.98% and 77.99% respectively with AECF₅₀ and AECF₁₀₀ for the duration treatment 15 days. With respect to the 30-day treatment duration, the increase is 82.76% with the two doses used. The number of primary follicles and primordial follicles grouped under the name of other follicles, did not show a significant increase (p >0.05) of its number with the treatment of duration 30 days at the dose of 100mg/kg of BW (AECF₁₀₀). This increase is 63.25% compared to controls. Any other observed increase in these follicles is not statistically significant (p > 0.05).

Effects of the Extract on the Histological Structure of the Uterine Horns

Table 2: Effect of *Cnestis ferruginea* on the histological structure of the uterine horns of rats after 15 and 30 days of treatment.

Uterine parameters	15 Days			30 Days		
	Control	AECF ₅₀	AECF ₁₀₀	Control	AECF ₅₀	AECF ₁₀₀
Lumen Diameter of uterine horns (µm)	498,70±37,74	658,40±69,31*	694,57±13*	535,50±41,91	763,60±78,13*	815,10±57,63*
Thickness of endometrium (µm)	388,30±57,24	528,40±36,67	664,80±43,65*	464,80±36,04	724,40±39,76*	669,40±77,25*
Height of epithelial cells (µm)	18,04±1,05	23,35±0,62	26,76±1,49*	17,24±0,82	26,21±3,14*	26,84±1,83*
Number of uterine glands (µm)	23,43±3,46	24,69±0,73	25,12±2,36	26,33±2,39	29,00±1,86	36,83±3,70*
Diameter of uterine glands (µm)	38,01±2,13	55,64±1,64*	54,98±2,64*	37,17±4,01	60,34±2,73*	64,84±7,49**

Note: Values are means ± SEM (n=6); * = p<0.05; ** = p<0.01. Control: Distilled water, AECF₅₀: Aqueous Extract of *C. freruginea* (50mg/kg of body weight), AECF₁₀₀: Aqueous Extract of *C. freruginea* (100mg/kg of body weight).

Histological studies performed on the uterine horn (Figure 2) showed a significant increase (p <0.05) in the lumen diameter of this organ regardless of the duration of treatment and the dose of the extract administered. Indeed, the treatment of duration 15 days showed an increase of 32.02% and 39.28% respectively for

AECF₅₀ and the AECF₁₀₀. The results also showed a rate of increase of 42.60% and 52.21% respectively for AECF₅₀ and AECF₁₀₀ after 30 days of treatment. At the endometrial level, the extract at the dose of 100mg/kg BW (AECF₁₀₀) caused a significant increase (p <0.05) in its thickness after 15 days of treatment. This increase is 71.21%

compared to controls. After 30 days of treatment, this tissue has grown significantly ($p < 0.05$) by 55.85% and 44.01% respectively with AECF₅₀ and AECF₁₀₀ compared to controls. The increase in endometrial thickness induced by AECF₅₀ is not significant.

Concerning epithelial cells, the extract showed a significant ($p < 0.05$) increase of 48.32% in height after 15 days of treatment with EACF100. While the increase induced by the EACF₅₀ is not significant.

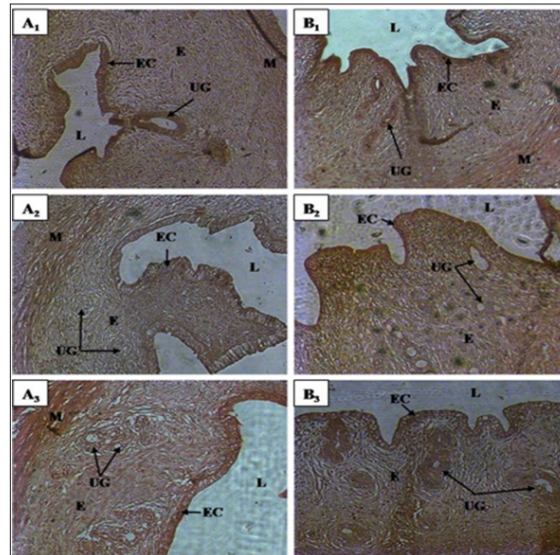


Figure 2: Uterine horn micrographs of control and treated rats with *Cnestis ferruginea* at 15 and 30 days

A1: Contol (15 days);

A2: Treated 50 mg/kg BW (15 days);

A3: Treated 100 mg/kg BW (15 days)

B1: Control (30 days);

B2: Treated 50 mg/kg BW (30 days);

B3: Treated 100 mg/kg BW (30 days)

EC: Epithelial cells; E: Endometrial; UG: Uterine gland; L: Lumen; M: Myometrium.

At the end of 30 days of treatment, the results showed a significant ($p < 0.05$) increase of 44.02% and 55.68% respectively with AECF₅₀ and AECF₁₀₀ of epithelial cell height compared to controls. The number of uterine glands did not increase significantly ($p < 0.05$) after 30 days of treatment with AECF100. All other increases are not statistically significant ($p > 0.05$). It should be noted that with the 30-day treatment, the results showed a beginning of necrosis of the uterine glands and epithelial cells in 50% of the rats treated with EACF₁₀₀. In this study, measurement of uterine gland diameters showed that all doses administered increased significantly regardless of the duration of treatment. Thus, after 15 days of treatment there was an increase of 46.38% ($p < 0.05$) and 44.64% ($p < 0.05$) compared to controls. After 30 days of treatment, rates of 62.34% ($p < 0.05$) and 74.44% ($p < 0.01$) increase relative to the controls (Table 2) are obtained.

Discussion

The results obtained on the structure of the ovaries indicate that the extract of *C. ferruginea* induces a significant increase in the number of corpus luteum. The corpus luteum being a product of ovulation, increase of these shows an inducing effect of ovulation by the plant extract. These results corroborate those of

administration of extract mixture of *Medicago sativa* (Fabaceae) and *Salvia officinalis* (Lamiaceae) to female mice [5]. These results are contrary to those obtained by Kouakou [6]. Indeed, this author administered extracts of *Daldinia concentrica* (Xylariaceae) and *Psathyrella effluvescens* (Coprinaceae) to rats and recorded a significant reduction in the number of corpus luteum. These results could be an effect of the extract at the central level by stimulating the release of LH whose peak corresponds to ovulation. It is established that ovulation is comparable to an inflammatory process [7]. Thus, the extract appears to stimulate the activation of the genes involved in the prostaglandin and leukotriene synthesis cascade to induce ovulation. Otherwise, studies by Lim et al. [8] found that cyclooxygenase-deficient (COX-2) mice suffer from defects in reproductive functions such as ovulation and fertilization. Indeed, this enzyme is very important in ovulation because of its essential role in follicular rupture. The extract may exert an activating effect on COX-2 or stimulate its production to induce ovulation and in turn the increase in the number of corpus luteum.

The effect of the extract is not limited only to the induction of ovulation. It extends to all folliculogenesis. Indeed, folliculogenesis according to Monget et al. [7] occurs in two phases: the regulation

of the first phase (basal phase) that extends from the primordial follicle to the tertiary follicle is intra-ovarian and the second phase of the tertiary follicle to ovulation is entirely dependent on the gonadotropins. According to Vaissaire [9], the growing follicles exert an inhibition on the exit of the new follicle. Thus, during the first phase, the extract could stimulate the follicle recruitment by lifting this inhibition somewhat. This would explain the increase in the number of primordial, primary, and tertiary follicles found in this study. Concerning De Graaf follicles in the second phase of folliculogenesis, its increase in this study could be explained by a central action of the extract to stimulate the release of FSH. In addition, the extract could activate IGF-I which is a growth factor and plays a key role in the transition from basal folliculogenesis to gonadotropin-dependent folliculogenesis. This result also confirms the high number of corpus luteum recorded in this study.

Histological studies performed during this experiment showed a significant increase in uterine horn diameter, endometrial thickness, height of epithelial cells, uterine gland diameter, and uterine gland number in rats treated with the plant extract compared to the controls group. Similar results were obtained by Bleu et al. [10] after the administration of aqueous extract of *Passiflora foetida* and 17β -oestradiol to ovariectomized immature rats. Concerning the height of the epithelial cells and the diameter of the uterine glands, these results are similar to those of Adaay and Mosa [11]. Indeed, these authors administered the aqueous extract of *Tribulus terrestris* (Zygophyllaceae) to the mice and obtained a significant increase in these parameters.

Otherwise, the increase in the above-mentioned parameters completed by the onset of necrosis of the uterine glands and epithelial cells observed accurately reflects the characteristic manifestation of estrus at the structural level of the uterus in the rat. Indeed, Westwood [12] studying the structures of the organs of the reproductive tract according to the stages of the estrus cycle in the rat has been able to establish that the estrus is marked in the uterus by a degeneration of the uterine glands, followed by the epithelial cells.

This is accompanied by a loss of mitotic activity and infiltration of leucocytes. The dilation of light may persist until the end of estrus, although this is not usually the case. In addition, the increase in endometrial thickness in this study may be related to stimulation of mitotic activity in the endometrium induced by the plant extract. Indeed, Westwood [12] reported a recovery of mitotic activity towards the end of estrus. This activity could be stimulated rather by the extract to amplify the mitotic activities induced during the proestrus phase [13,14]. Regarding epithelial cells, Soto et al. [15] reported that systemic and local IGF-I plays an important role in the effect of estrogen on the growth and epithelial proliferation of the mouse uterus. The extract of *C. ferruginea* could stimulate the production of IGF-I and induce the effects observed in the treated rats. It should be noted that any cellular proliferative activity that takes place in the uterus of rodents depends on a direct action of estrogen [16]. The extract could directly stimulate cell proliferation by having it as an estrogen-like one or by stimulating the release of estradiol. Ultimately, the aqueous extract of *Cnestis ferruginea*

induced stimulation of folliculogenesis by increasing the number of follicles at different stages of evolution. This plant extract also induces ovulation. On the uterus, *C. ferruginea* causes the manifestation of estrus and behaves like endogenous estrogen.

Acknowledgement

The authors are indebted to Dr. Mangué N'Tapké Emmanuel Jaurès (Director of the Laboratory of Endocrinology and Reproductive Biology) to have available all the necessary equipment for this work.

References

- Verlet N (1990) New markets for herbs in France and Europe. *Herb Spice Med Pl Digest* 8: 1-5.
- Balandrin MF, Kinghorn AD, Farnsworth NR (1993) Plant-derived natural products in drug discovery and development-an overview. In *Human medicinal agents from plants*. (Eds.) AD Kinghorn and MF Balandrin Am Chem Soc, San Francisco, Canada, p. 2-12.
- Tra Bi FH (1997) Utilisation des plantes, par l'homme, dans les forêts classées du Haut-Sassandra et de Scio, en Côte d'Ivoire. Thèse de doctorat 3e cycle, Université d'Abidjan Cocody, pp. 215.
- N'guessan K, Kouadio K, Kouamé NF (2006) Plantes emménagogues utilisées en médecine traditionnelle par les peuples Abbey et Krobou d'Agboville (côte d'ivoire). *Parm Méd Afr* 14: 137-158.
- Adaay MH, Al-Dujaily SS, Ferial K, Khazzal FK (2013) Effect of aqueous extract of *Medicago sativa* and *Salvia officinalis* mixture on hormonal, ovarian and uterine parameters in mature female mice. *J Mater Environ Sci* 4(4): 424-433.
- Kouakou K (2000) Etude des effets antifertilisants de l'extrait de deux champignons (*Daldinia concentrica*, Bolt. 1863 et *Psathyrella efflorescens*, Berk, 1977) de la pharmacopée ivoirienne chez la ratte. Thèse de Doctorat 3ème cycle, Université de Cocody-Abidjan, pp.122.
- Monget P, Hembert S, Binart N, Gougeon A, Panthier JJ (1999) La physiologie ovarienne: ce que nous disent les souris. *Med Sci (Paris)* 15(2) : 141-147.
- Lim H, Paria BC, Das SK, Dinchuk JE, Langenbach R, et al. (1997) Multiple female reproductive failures in cyclooxygenase 2-deficient mice. *Cell* 91(2): 197-208.
- Vaissaire JP (1977) Sexualité et Reproduction des mammifères domestiques et de laboratoire. Paris Maloine Editeur 457.
- Bleu GM, Kouakou K, Zahoui OS, Touré A, Traoré F (2012) Oral acute toxicity and estrogenic effects of the extracts of *Passiflora foetida* Linn. (Passifloraceae) leaves in female Wistar albino rats. *Ann Biol Res*, 3(9): 4609-4616.
- Adaay MH, Mosa AR (2012) Evolution of the effect of aqueous extract of *Tribulus terrestris* on some reproductive parameter in mice. *J Mater Environ Sci* 3(6): 1153-1162.
- Westwood FR (2008) The female rat reproductive cycle: a practical histological guide to staging. *Toxicol Pathol* 36(3): 375-384.
- Wheater PR, Burkitt GH, Daniels VG, Deakin JP (1979) Histologie fonctionnelle. Ed Médecine et sciences Internationales (MEDSI) 278.
- Russell WF (2008) The female reproductive cycle: a practical histological Guide to standing. *Toxicol Pathol* 36(3): 375-384.
- Soto M, Maeba H, Watari J, Takashio M (2002) Analysis of an inactivated Lg-FL01 gene present in bottom-fermenting yeast. *J Biosci Bioeng* 93(4): 395-398.
- Tong W, Pollard JW (2002) In The endometrium. Glasser SR, Aplin JD, Giudice LC, Tabibzadeh S, (Eds.) Taylor and Francis, London, pp. 94-109.

